

A Web-Based Guide to the Diagnosis and Treatment of Chronic
Ophthalmic Pathologies

by

Carlee Taylor

Submitted in partial fulfillment of the requirements for graduation as an Honors Scholar at
Point Loma Nazarene University, San Diego, California, May 4, 2019.

Approved by _____
Dr. Leon Kugler

Dr. Brandon Sawyer

Date _____

ABSTRACT

Chronic ophthalmic pathologies are a prevalent cause of blindness and vision impairment (VI) in the world. There are an estimated 1.02 million people who are blind, 3.22 million people with vision impairment, and 8.2 million people living with correctable vision impairment.¹ Glaucoma, age-related macular degeneration, cataract, cancers, and diabetic retinopathy are the prominent pathologies among the many that can cause vision impairment or vision loss. These pathologies disproportionally affect the elderly and can significantly affect quality and safety of daily life, mentally and physically. Those with vision impairment are more likely to suffer from trauma due to falls and driving accidents, develop other chronic conditions, and suffer from depression.^{2,3,4} The purpose of this project is to generate a web application, targeted for Pre-health care students and professionals, for the diagnosis and treatment of those suffering from VI or vision loss due to ocular and systemic pathologies. The web application will provide epidemiology, etiology, pathogenesis, clinical manifestations, treatment, and prognosis for pathologies that cause blindness or vision impairment. The guide will be based on an extensive evidence-based literature review, cadaveric dissection, and pedagogical technical studies and practice.

IDENTIFICATION OF THE RESEARCH PROBLEM AND REVIEW OF THE LITERATURE

Introduction

Chronic ophthalmic pathologies are a prevalent cause of blindness and vision impairment in the Western world. The prevalence of vision loss or impairment is estimated to affect 2.94% of the United States population with 30% of those individuals over 75 years of age.¹ According to Wittenborn and colleagues, approximately 2.14 million persons aged 18-39 years of age are affected by 13 different pathologies.⁵ Those with VI and vision loss experience a significant effect on productivity, incidence of chronic health conditions, social relationships, emotional well-being, physical safety, and independence of the individuals impacted, adversely affects our society as a whole, monetarily and socially. An estimated \$35.4 billion is spent on major adult visual disorders annually.⁶ Health-related quality of life (HRQOL) associated with vision impairment decreases as severity of vision loss increases. Individuals will experience fair/poor health, life dissatisfaction, disability, unhealthy physical and mental health days, and activity limitation.^{3,4}

The majority of these conditions rely on preventative screening to avert progression of vision loss. The most prevalent ocular diseases in the elderly are cataracts, glaucoma, and age-related macular degeneration (AMD). The increase in cataract surgery has greatly improved the impact of cataract; however, the effects of glaucoma and AMD are irreversible. Prevention of these chronic diseases is paramount. Patient education and access to eye care, especially for at-risk populations of the various chronic ophthalmic pathologies, can dramatically impact quality of treatment and daily life. In at-risk populations for the most impactful ocular diseases, there is an underutilization of eye-care due to socioeconomic factors, education level, and physician-patient relationship, cultural barriers, and insurance.^{7,8} With the aging of the United States population, the incidence of these diseases will more than double.¹

The purpose of this study is to create a reference tool for pre-health students, Allied health clinicians, and those affected by chronic ophthalmic pathologies who may be treating or experiencing vision impairment. This pedagogical tool will provide a convenient guide to the epidemiology, etiology, pathogenesis, clinical manifestations, diagnosis, and treatment. Many of the chronic ophthalmic pathologies' pathogenesis are still unknown, this guide will delve into the current theories. It will educate those going into the health field, so they can better understand the long-term diseases that affect the eye.

METHODS

Design and Data Collection Procedures

A literature review of peer reviewed journals and medical reference materials were completed to ensure current insights into the chosen diseases. Only data from an authoritative medical authority website was used. CINAHL Plus and MEDLINE search engines were utilized primarily. No human subjects will be used in this study. Cadaveric dissection figures contribute to overall understanding of the anatomy and function of structures of the ocular region. Also, serves as a frame of reference for those unfamiliar with the anatomy. The cadaveric dissection

was conducted using one specimen. The extrinsic eye muscles were dissected bilaterally from both the superior and anterior directions.

Pathologies were included in the guide based off epidemiology, chronic versus acute, region of ocular area (retina, lens, cornea, etc.), and extent of vision impairment. Diseases included are cataract, glaucoma, age-related macular degeneration, diabetic retinopathy, keratoconus, pellucid marginal degeneration, post-surgery corneal ectasia, hypertensive retinopathy, retinoblastoma, Fuch's corneal dystrophy, herpes zoster ophthalmicus, amblyopia, retinitis pigmentosa, and retinal detachment. The final list was discussed with an optometrist to determine clinical relevance of diseases. Website was organized by pathology and includes specific sections on epidemiology, etiology, pathogenesis, clinical manifestations, effect on vision, diagnosis, and treatment for each pathology. Vision impairment is determined as best-corrected vision in better-seeing eye that is worse than 20/40, but better than 20/200. Blindness is categorized as a visual acuity 20/200 or worse.

SIGNIFICANCE OF PROPOSED RESEARCH

Anticipated Outcomes

This project will be useful to undergraduate and medical students, allied health professionals, and patients who work with or will develop chronic ophthalmic pathologies. The goal is to provide a resource of current information for those interested and wanting to learn about these conditions. It will provide an in-depth analysis of the epidemiology, current developments in the pathogenesis, diagnosis, and treatment of the pathologies.

Relevance to Allied Health

The web-based guide will enhance the knowledge and education of allied health professionals, professors, and students. It will serve as a reference tool and reminder regarding the significance of early-prevention, screening, and impact of regular eye-care in treatment of ocular diseases. Due to the aging of the United States population, the number of individuals impacted with VI or blindness is predicted to greatly increase, by 2050 the number of affected will double.¹ The web-based guide will serve as a easy to use resource for pre-health students, clinicians unfamiliar with ocular diseases, and patients to learn the epidemiology, pathogenesis, clinical manifestations, and treatment of ocular diseases. Allied health students and professionals will have a reference tool to better serve their patients by learning the epidemiology and typical presentations of chronic ocular diseases. It is essential that pre-medical students and medical professionals can distinguish between and identify these chronic ophthalmic pathologies.

EYE ANATOMY

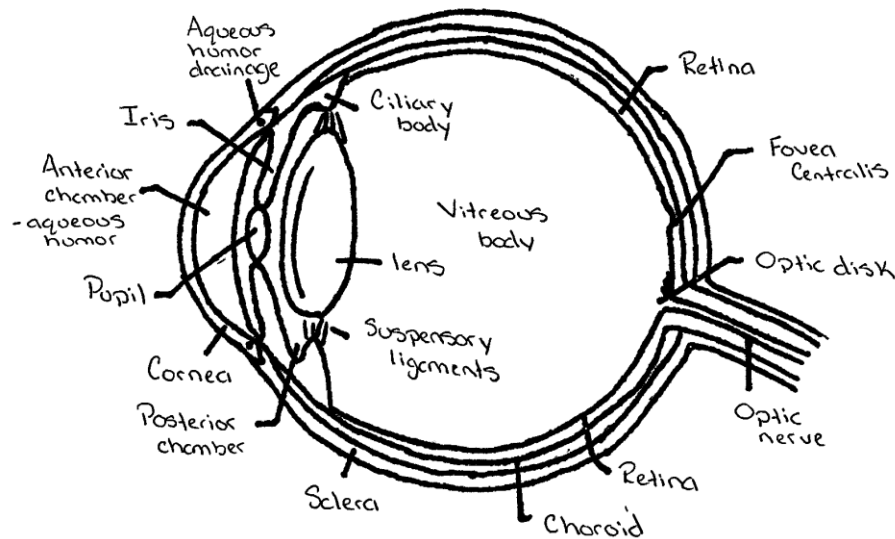


Figure 1: Sagittal view of the eye displaying key anatomical structures of the eye.

The eye is a complex sphere enclosed by three distinct layers and fluid-filled. The outermost layer is the sclera, a tough, white, fibrous tissue acting as a point of attachment for the extrinsic eye muscles. The cornea is a transparent tissue continuous with the sclera that contributes to the majority of light refraction and inverts the image as light enters the eye. The innermost layer of the eye is the retina, composed of neurons that capture light and send visual signals to the brain. The middle layer is referred to as the uveal tract, composed of three distinct, continuous layers (choroid, ciliary body, and iris). The choroid, the largest layer, contains a capillary bed necessary to transport nutrients to the retina and contains the light-absorbing pigment melanin. Melanin is located in the pigment epithelium directing adjacent to the retina and absorbs excess light not captured by the retina. The ciliary body encircles the lens with a muscular and vascular portion. The muscular portion of the ciliary body adjusts the refractive power of the lens by changing tension placed on the lens through the suspensory ligaments. The suspensory ligaments are attached to both the ciliary muscle and the lens. The ciliary processes, vascular portion, secretes and produces fluid found in the anterior compartment of the eye. The aqueous humor is a clear, watery fluid produced in the posterior chamber that enters the anterior chamber through the pupil and provides nutrients to the lens. Aqueous humor is drained through the trabecular meshwork located at the base of the cornea near the ciliary body. The iris, the colored portion of the eye, is a set of muscles that change the size of the eye opening, the pupil.

As light is refracted by the lens, it continues through the vitreous humor and is focused on the retina. The vitreous humor fills the posterior chamber, the back of the lens to the retina. The vitreous humor maintains the shape of the eye and contains phagocytic cells that remove blood and debris from the chamber. As the eye ages, large pieces of debris collect as the phagocytic cells failed to clear and cause floaters to appear in the visual field. The retina is composed of photoreceptors, bipolar cells, and retinal ganglion cells (RGC). Most importantly the photoreceptor cells. Photoreceptor cells located at the most posterior retina detect light and made up of two cell types: rods and cones. Rods detect low light and primarily located on the

peripheral retina. Cones are responsible for color vision and detect intense light. Macula is a yellow pigmented circle located near the center of the retina. The center of the macula is referred to as the fovea centralis and is location of highest visual acuity. Also, the fovea has the highest density of cones. The visual signal is transmitted from the photoreceptors to the bipolar cells to the retinal ganglion cells to the optic nerve. The photoreceptors are the farthest posterior so light must first pass through the RGC and the bipolar cells, respectively, to reach the photoreceptors. The optic nerve is the location of all of the retinal ganglion cells exiting the eye. No photoreceptors exist at the optic nerve and is a blind spot. A blind spot is a visual field deficit known as scotoma. The brain fills in the scotoma created by the optic nerve with the opposing eye's visual field.

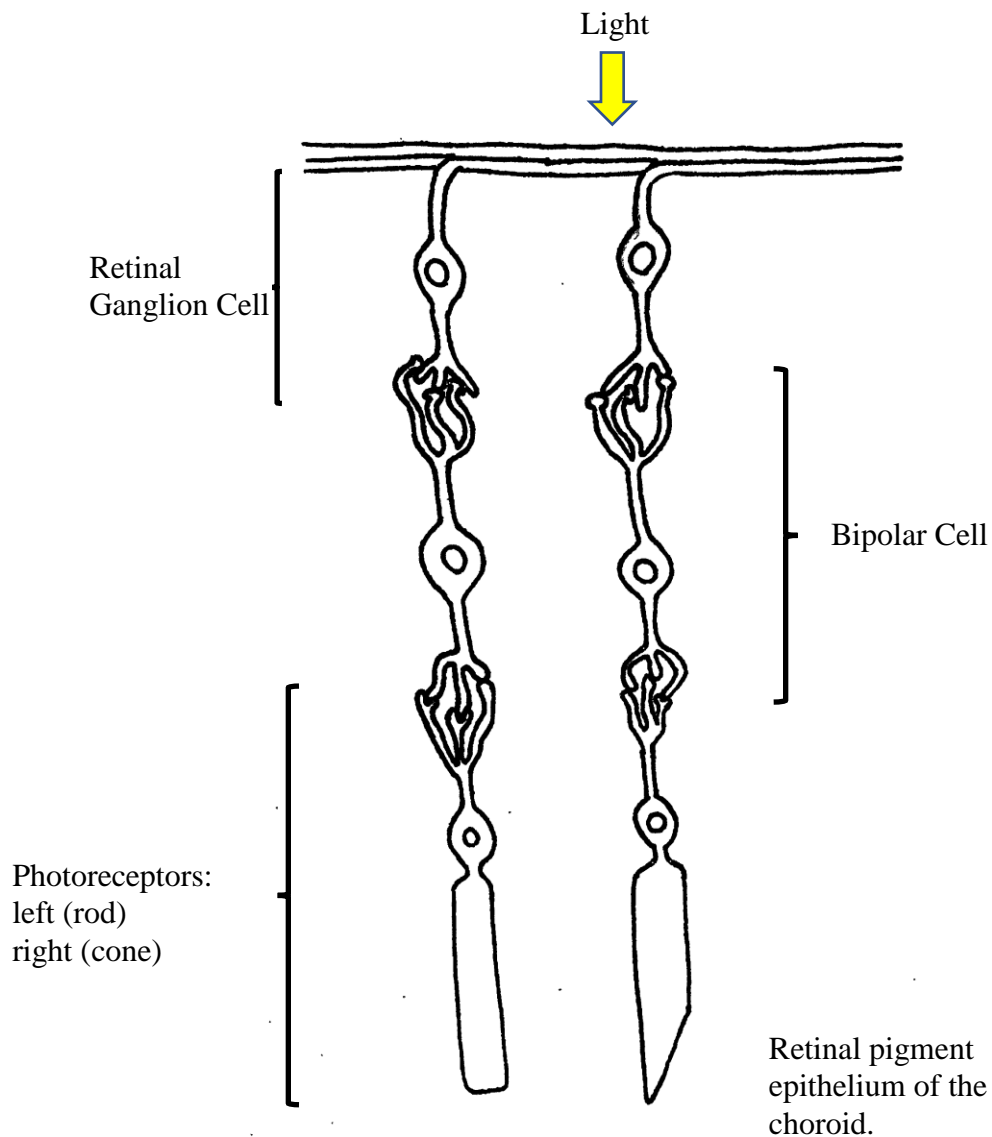


Figure 2: Retinal Structures of the photoreceptors (rods and cones), bipolar cells, and retinal ganglion cells.

Table 1: Anatomical structures affected by respective pathology.

Anatomy Affected	Pathology
Cornea	Keratoconus, Pellucid Marginal Degeneration, Post-surgery Corneal Ectasia, Fuch's Corneal Dystrophy
Lens	Cataracts
Retina	Diabetic Retinopathy, Hypertensive Retinopathy, Retinitis Pigmentosa, Retinoblastoma
Macula	Age-related Macular Degeneration
Optic Nerve	Glaucoma
Visual Processing	Amblyopia (strabismus)

Extrinsic Eye Muscles

The extrinsic eye muscles all attach to the sclera. The superior oblique muscle originates in the upper, medial side of the orbit and inserts on the superior lateral portion of the globe. The superior oblique runs along a site of attachment, the trochlea, to obtain the angle to abduct, depress, and internally rotate the eye. The inferior oblique originates in the lower, medial side of the orbit and inserts on the inferior globe. It abducts, elevates, and externally rotates the eye. The superior rectus muscle elevates the eye. The inferior rectus muscle depresses the eye. The medial rectus muscle is the primary adductor of the eye and the lateral rectus is the primary abductor of the eye. The levator palpebrae superioris elevates the eyelid.

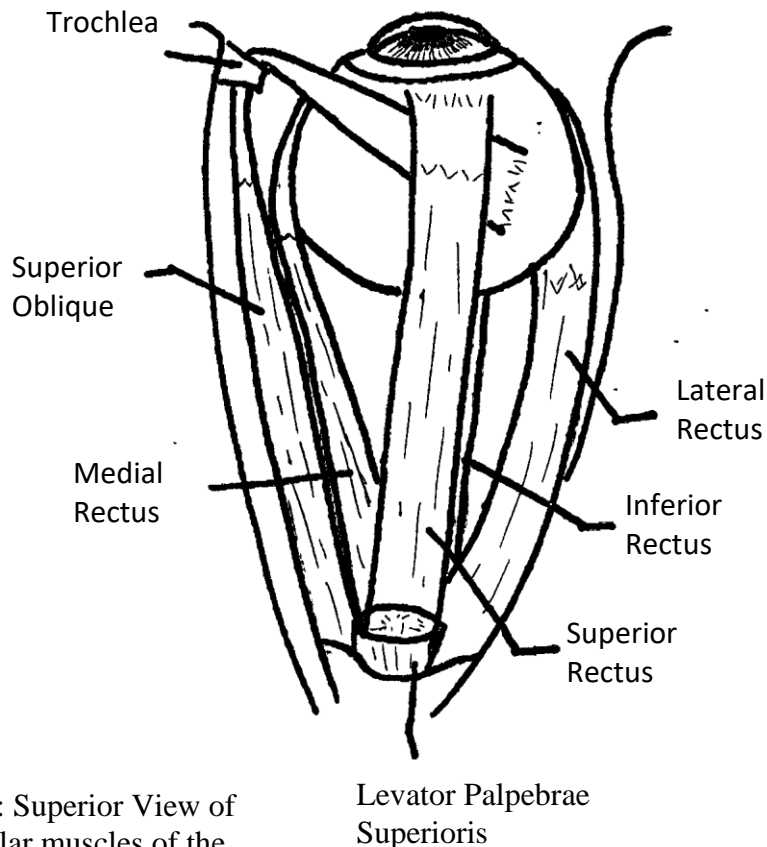


Figure 3: Superior View of extraocular muscles of the right eye.

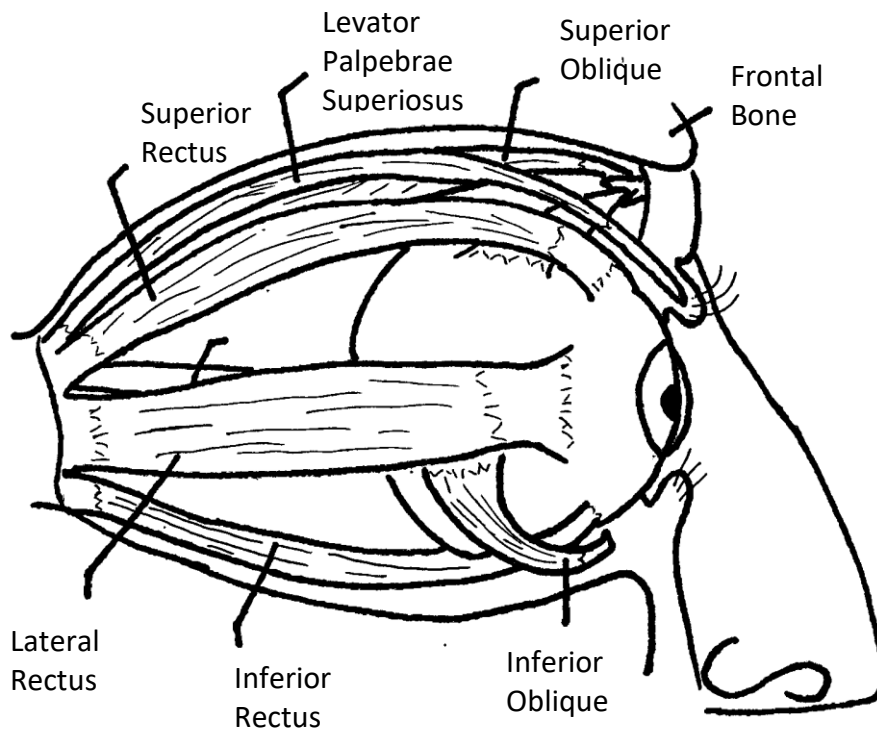


Figure 4: Lateral surface displaying the extraocular muscles of the right eye.

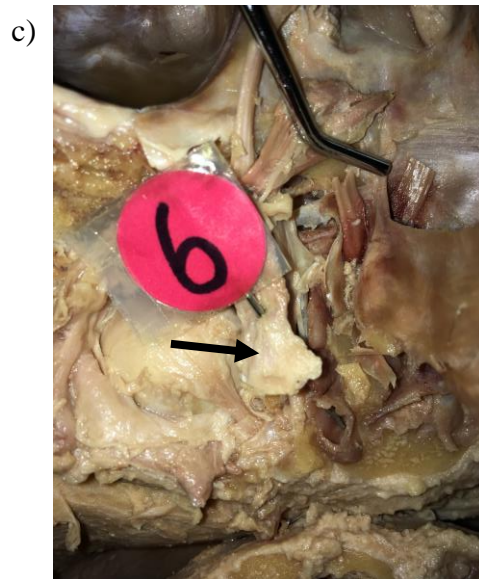
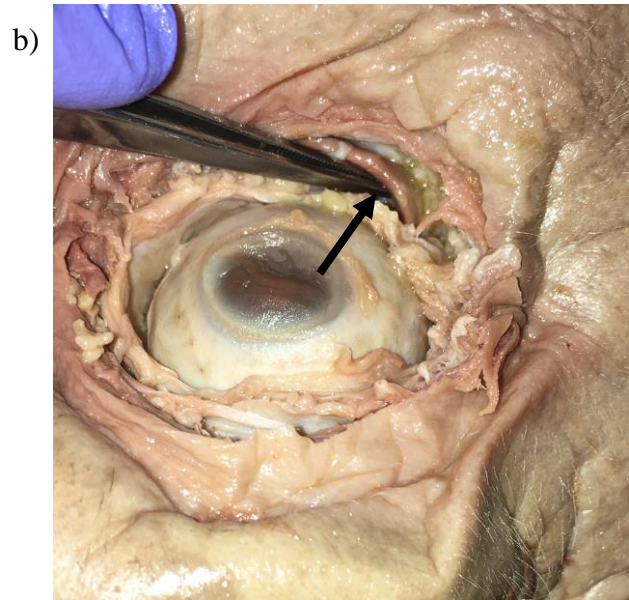
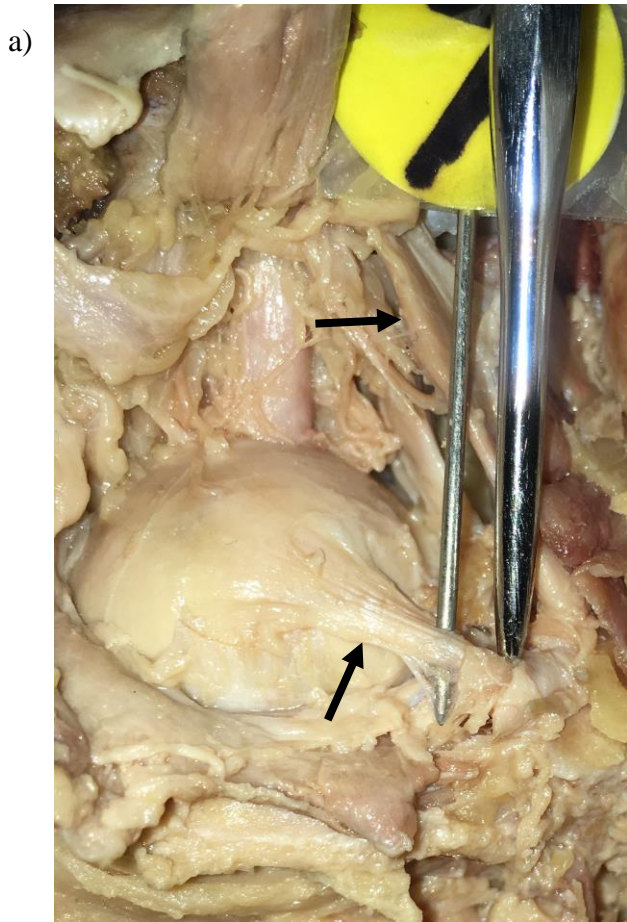


Figure 5: Superior view of the extraocular muscles of the right eye

- a) Black arrow dictates the superior oblique muscle traveling through the trochlea (bordered by dissection tools)
- b) Black arrow denotes the muscle body of the inferior oblique muscle.
- c) The superior rectus is shown.

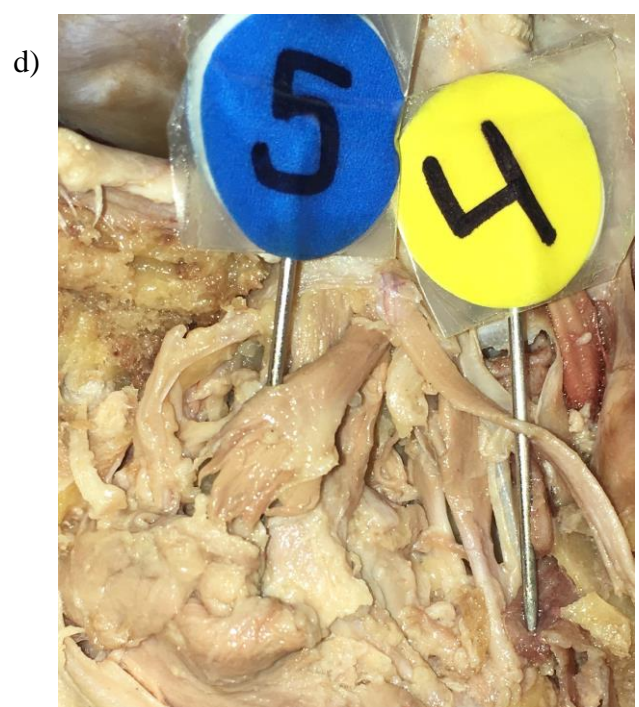
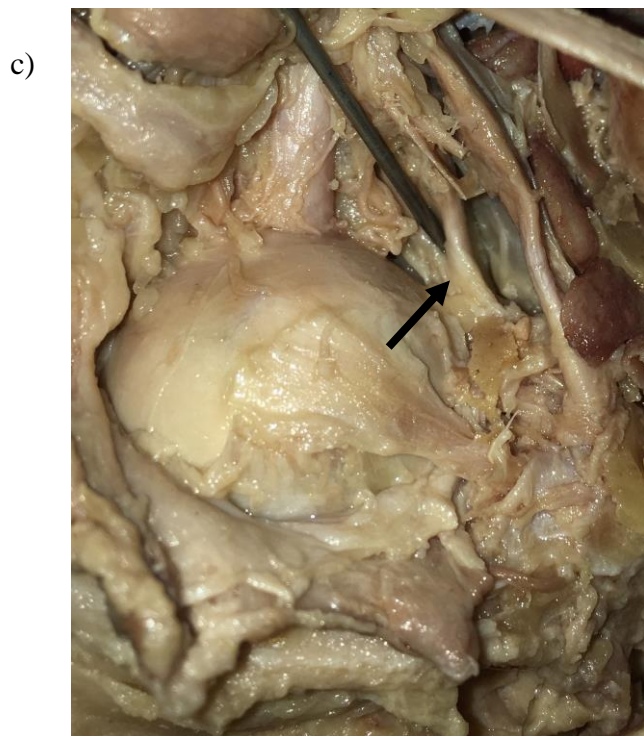
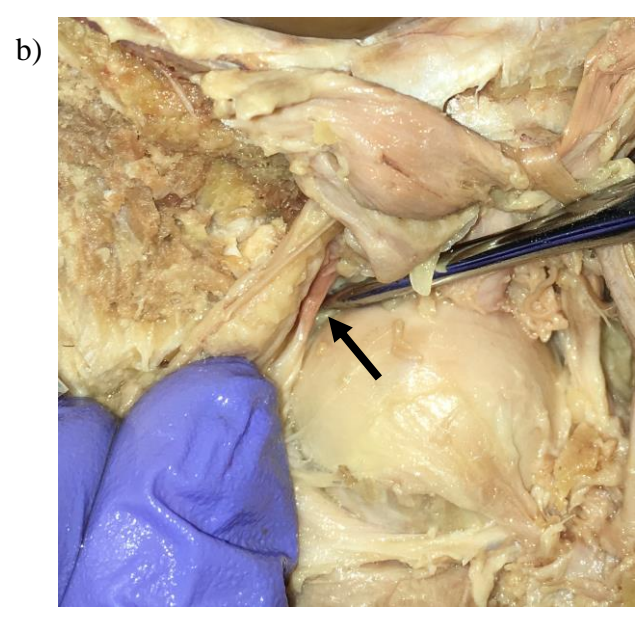
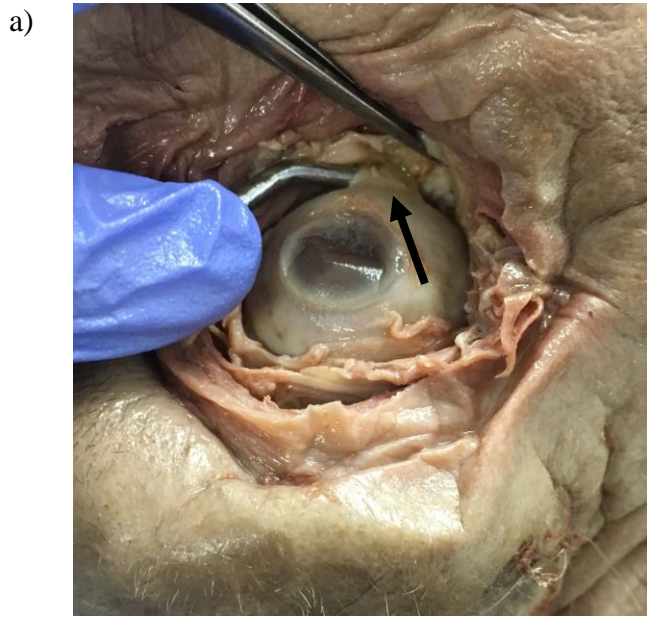


Figure 6: Superior view of the extraocular muscles of the right eye with black arrow denoting respective muscle.

- a) Inferior rectus muscle is under tension by the probe
- b) Lateral rectus muscle (red tissue)
- c) Medial rectus
- d) Levator palpebrae superioris labeled by #5 pin and trochlear nerve labeled by #4 pin.

PATHOLOGIES

The complex structure of the eye is apparent in the various pathologies that affect the ophthalmic region. The following pathologies included are: cataract, glaucoma, age-related macular degeneration, diabetic retinopathy, keratoconus, pellucid marginal degeneration, post-surgery corneal ectasia, hypertensive retinopathy, retinoblastoma, Fuch's corneal dystrophy, herpes zoster ophthalmicus, amblyopia, and retinitis pigmentosa. The following section provides an overview of the populations affected, diagnostic criteria, signs and symptoms, and current treatment options.

Cataract

Overview

Cataract is the congenital or degenerative loss of the transparency of the lens due to protein aggregation within the lens. The lens is a clear structure located posterior to the iris and pupil focuses light on the retina. As the lens ages or is damaged, it can become cloudy as proteins clump together. The light is scattered by the cloudy lens before it reaches the retina, which distorts the image. It is the leading cause of vision impairment and one of the leading causes of blindness in the United States.¹⁰ The type of cataract is determined by the location: cortical, nuclear, and posterior subcapsular. Nuclear and cortical cataracts form in the portion of the lens their adjective denotes. Posterior subcapsular are present anterior to the posterior capsule. Cortical and nuclear cataracts are most commonly associated with aging and UV radiation. Congenital cataracts can appear at birth or during early childhood and can be nuclear, cortical, or subcapsular. The risk factors associated with congenital cataracts are a prenatal infection and a family history (specific genetic mutations).¹¹ Anterior polar cataract, specific type of congenital cataract can be spontaneous or familial.¹² Early stage treatment of cataracts is with corrective lens; later as vision affects daily activities, surgery is performed to replace the lens that significantly improves vision. This is considered a preventable cause of blindness and vision impairment.¹³

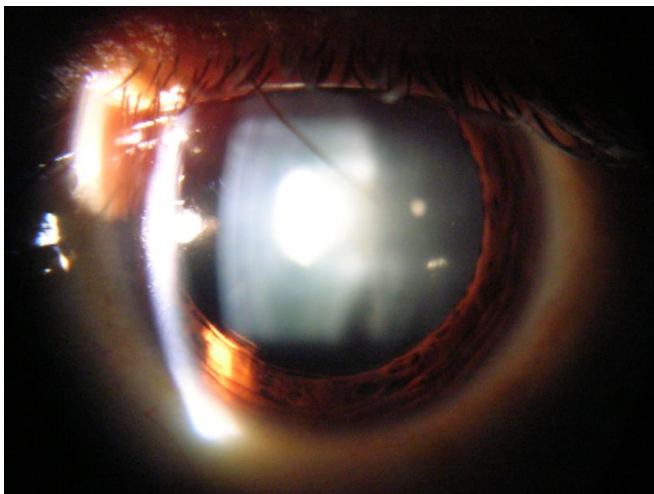


Figure 7: Slit-lamp view of human cataract.¹⁴

Epidemiology

Cataracts cause low vision in 59% of white individuals, 51% of black individuals, and 47% of Hispanic individuals. It causes blindness in 9% in white individuals, 37% in black individuals, and 14% in Hispanic individuals. Females tend to have a higher prevalence of cataracts than males at 61% to 39%, respectively.^{10,15} The aging population is at a higher risk of developing cataracts with 50% of persons affected over the age of 75.¹⁵

Risk Factors

There are various risk factors associated with developing cataracts that include environmental and genetic factors. As a person ages, the risk of developing cataracts increases.¹⁶ Exposure to UV radiation from not wearing outdoor eye-protection or exercising outside increases the chances of developing cataracts.¹⁷ Increased duration of exercise is also associated with cataracts due to the production of free radicals and exposure to UV radiation leads to oxidative stress.¹⁶ Females have a higher prevalence of cataracts.^{10,13,16} Those who currently smoke, or previously smoke cigarettes are at a higher risk.^{17,18} A diet low in antioxidants may contribute to the development of cataracts due to lack of nutrients in body to minimize oxidative stress.¹⁹ Trauma to the eye, including previous surgery, and a variety of adverse effects of medications, corticosteroids, chlorpromazine, and other phenothiazine-related medications.^{16,20} Systemic diseases such as diabetes and hypertension are also associated with cataracts.²¹ Myopia and iron deficiency anemia, high TIBC levels, are risk factors for cataracts.^{17,22,23} Different genetic mutations predispose individuals to the development of cataracts.²⁴ Posterior subcapsular cataracts occur mainly in the younger population and associated with prolonged corticosteroid use, inflammation, diabetes, and trauma.²⁵

Diagnosis

Diagnosis and grading of cataract is accomplished using a slit-lamp tool and classifying via the Lens Opacification Classification System III (LOCS). The system uses different slit-lamp images to grade nuclear, cortical, and posterior subcapsular cataract.²⁶

Pathogenesis

The formation of cataracts is not fully understood and is most likely due to the interaction of environmental, genetic, nutritional, and systemic factors.²⁷ Lens proteins are not replenished throughout the life of the lens and as we age, the proteins unfold, especially in the central portion.²⁸ Oxidative stress is highly implicated in the pathophysiology which is accumulated as the lens ages and is exposed to different environmental factors.^{16,29} The antioxidant, Glutathione (GSH), prevents oxidation of the lens, but as the lens ages the levels of GSH decrease. As a result, the levels of disulfides increase that leads to an increase in oxidative stress. GSH levels decrease because lens proteins are not replenished and the diffusion of GSH through the cortical and nuclear portion of the lens decreases with time.²⁷ A chaperone protein, α -crystallin, prevents

denatured proteins from precipitating and clumping together. There is only a finite amount of α -crystallin in each lens and if mutations occur, it can lead to the development of cataracts.³⁰

Signs and Symptoms

Patients may complain of a glare, loss in contrast, painless blurring, or needing more light to see. Those with presbyopia may be able to read without glasses. Also, those with hyperopic eyes (far-sighted) may experience a “second sight” as they are able to read without glasses.³¹ Difficulty driving, especially at night due to red/green disability glare (DG) is observed by those with cataracts.³² Those with presbyopia may also experience a similar phenomenon. This is most common in nuclear cataract. Posterior subcapsular cataract typically experience disproportionate vision loss.³³

Treatment

Corrective lenses are prescribed throughout disease progression. A diet high in anti-oxidants such as Vitamin C and manganese can be beneficial in slowing the progression.¹⁹ Surgical options including replacing the lens with a pseudophakia, artificial lens, via small incision cataract surgery (ICCE) or extracapsular cataract surgery (ECCE). ICCE is an older version of cataract surgery that removes the entire lens. This surgery is performed when ECCE is contraindicated and mainly in developing countries.³⁴ ECCE is done using phacoemulsification with intraocular lens (IOL) implantation. Phacoemulsification is the lens being broken down into smaller pieces by an ultrasonic hand piece and aspirated from the eye. The replacement lens may be a multifocal or unifocal intraocular lens.^{35,36} Those with multifocal IOL are less likely to be spectacle dependent; however, some multifocal patients underwent a secondary surgery to exchange IOL.³⁶ Current IOL technology has revolutionized cataract surgery by reducing dependence on spectacles for those with significant refractive error. “Secondary cataract” may occur after surgery that involves clouding of the lens. This occurs in 50% of patients and can occur months to years’ post-surgery.³⁷

Eyes with co-morbidities are commonly treated using the same techniques as eyes only affected by cataract. Treatment of eyes affected by cataract and glaucoma may or not be treated simultaneously. Combined cataract and microinvasive glaucoma surgery (MIGS) are common in patients with both glaucoma and cataracts, as IOP transplanted and phacoemulsification can be done at the same time as MIGS. MIGS can significantly improve quality of life of glaucoma patients by taking the place of topical medications that cause severe adverse effects.^{38,39} (Patrick Scott, O.D., email communication, March 5, 2019.) Fuch’s Corneal Dystrophy and cataracts are commonly treated simultaneously due to the probability of cataract surgery leading to worsening of Fuch’s dystrophy.⁴⁰

Overall an increase in dynamic vision is observed after cataract surgery and overall increase in quality of life.^{40,41} Post-surgery visual acuity is best predicted by the health of the optic nerve and retina, rather than the opacity of the lens. A systematic review by Riaz, found in studies comparing ECCE and phacoemulsification group, the phacoemulsification patients demonstrated greater improvement visual acuity than the ECCE patients. The ECCE patients also experienced

higher rates of astigmatism and higher complications during surgery.³⁴ Those with glaucoma and age-related macular degeneration also retain improvement in vision after surgery.⁴³

Glaucoma

Overview

Glaucoma is a progressive degeneration of the optic nerve due to elevated or normal intraocular pressure that can be distinguished by its characteristic cupping of the optic nerve. The determining factor for developing glaucoma is how retinal ganglion cells respond to stress, an increased intraocular pressure and/or lack of blood supply to the optic nerve. Elevated IOP is not necessary to cause optic neuropathy and may be caused by a specific combination of connective tissue geometry, blood supply, and reactivity to IOP. There are categories of glaucoma are primary open angle (POAG), primary angle-closure (PACG), pediatric glaucoma, and secondary glaucoma. POAG is characterized by improper drainage of fluid through the trabecular meshwork that results in a characteristic cupping of the optic nerve. PACG is caused by a small angle between the iris and cornea that prevents drainage of fluid that results in an acute increase in IOP. Glaucoma causes visual field deficits and eventual irreversible blindness if left untreated.⁴⁴ PACG is three times more likely to lead to blindness than POAG.⁴⁵ Pediatric glaucoma is split into congenital, infantile, and juvenile according to age of onset and is caused by angle deformities of the eye. Secondary pediatric glaucoma can be due to angle anomalies (Sturge-Weber syndrome,⁴⁶ Aniridia, anterior segment dysgenesis), retinopathy of prematurity, aphakia, intraocular inflammation, ocular tumors, trauma, and glucocorticoids.⁴⁷ Secondary glaucoma is due to other diseases or trauma processes such as pigment dispersion glaucoma, pseudoexfoliation glaucoma, etc.⁴⁸ Treatment varies according to the type of glaucoma.

Epidemiology

As of 2014, glaucoma affects approximately 3 million Americans and 64.3 million people worldwide^{49,50} By 2020, an estimated 3.4 million people within the United States will have glaucoma. POAG and PACG are both age dependent, primarily affecting those 75 years of age and older.⁵¹ Women are slightly more affected at 55% of cases,⁵¹ some studies have found not found an association between gender and glaucoma.^{52,53} POAG is most common in those of African descent and second most common in Hispanics and third in white persons;⁵⁴ however, PACG is most common in persons of Asian descent.^{49,51,55} Daily functioning is negatively affected by glaucoma with an increased incidence of driving accidents, falls,⁵⁵ and over-all quality of life and daily activity difficulties.^{57,58} Those with glaucoma are over three times more likely to have fallen in the last year and six times more likely to be involved in a traffic accident and be at fault.⁵⁶ Congenital glaucoma occurs in 1.46 per 100,000 children and occurs in infants and children. The incidence varies according to ethnicity.

Risk Factors

The different types of glaucoma vary in their respective risk factors. Primary open angle and closed angle glaucoma are both associated with increased age. Family history of the disease is associated with POAG, PACG, and pediatric glaucoma.^{51,59,60} Primary open glaucoma is associated with African ethnicity,^{49,51,55,61} post-menopause for women,^{62,63} myopia,⁶⁴ and increase in IOP.^{59,65} Systemic diseases are associated with POAG: type II diabetes,^{49,66} hypertension,^{59,67} and cardiovascular disease. Thinner central corneal thickness and disc area are risk factors for the development of POAG.⁵⁹ Primary angle closure glaucoma is associated with specific anatomical features of the eye including: crowded anterior segment, shallow anterior chamber depth, thicker and anteriorly positioned lens, and short axial length. Women and of Asian ethnicity are risk factors for PACG.^{49,51} Recent exposure to certain antidepressants drugs such as Topiramate,⁶⁸ TCAs, low-potency antipsychotics, and, to a lesser extent, and SSRIs.^{69,70} Family history is significant as a risk factor for pediatric glaucoma as the CYP1B1 gene is associated defects in angle development of iris to cornea. This is not seen in all cases. Prenatal infection may be a risk factor.

Pathogenesis

POAG has a reduced flow of the aqueous humor due to the degeneration and obstruction of the trabecular meshwork. As aqueous humor builds up, the IOP increases. For PACG, angle between the iris and the cornea, iridocorneal angle, is partially or completely closed leading to the buildup of aqueous humor. Pediatric glaucoma can be due to improper development the trabecular meshwork or iridocorneal angle leading to RGC death and increase in IOP. The relationship between the structural and function observed in glaucoma are complex with conflicting studies showing one change precedes the other. Both structural and functional changes are critical to the assessment and treatment of the disease.

The exact disease process leading to RGC death is unknown. The two major theories focus on the mechanical dysfunction of the cribriform plate and vascular dysfunction causing ischemia that may lead to optic neuropathy. Both, POAG and PACG can increase IOP which may displace the lamina cribosa (forms bottom of optic cup, LC). The LC is posteriorly displaced and thinned which disrupts axonal transport and causes mechanical axonal damage. This may lead to the characteristic cupping seen in glaucoma patients. Cupping is an increased disc to cup area due to optic neuropathy. Astrocytes found in POAG patients have decreased expression of angiogenic factors compared to normal astrocytes; therefore, do not contribute to the same degree to the remodeling of the LC.⁷¹ Vascular dysfunction may be due decreased angiogenesis, generation of new blood vessels, and production of reactive oxygen species. Hypertension also plays a role in the inadequate blood supply by damaging blood vessels due to the high blood pressure. The decrease in blood supply and an impairment in the mitochondria may lead to an increased dependence on glycolysis which produces reactive oxygen species. Reactive oxygen species can cause retinal ganglion cell apoptosis (programmed cell death).⁷² Normal tension glaucoma is most likely due to vascular insufficiency, since there is not an elevation in IOP. The pathogenesis of glaucoma could also be due to estrogen metabolism,⁶⁴ immune-mediated nerve damage, or deprivation of neuronal growth factors.

Secondary glaucoma is classified according to the known cause of increased IOP such as uveitis, trauma, pigment dispersion, pseudoexfoliation, glucocorticoid therapy, and vasoproliferative retinopathy. Uveitis is the inflammation of the uvea, middle portion of the eye including the iris, cornea, and choroid. A complication of uveitis is raised IOP. Pigment dispersion secondary glaucoma may occur when the pigment located on the iris comes off and blocks the drainage canal. Pseudoexfoliation glaucoma is the most common cause of secondary glaucoma and occurs due to an excess production of a protein found in the eye that can clog the trabecular meshwork. Proliferative retinopathy (neovascular glaucoma) can lead to the development and release of VEGF factors that can affect the anterior chamber of the eye. VEGF factors can lead to the neovascularization of the iris that may eventually grow into the anterior chamber angle narrowing the aqueous outflow and increasing the IOP. (Patrick Scott, OD., email communication, March 5, 2019)

Signs & Symptoms

Glaucoma is considered a silent stealer of sight because early signs and symptoms are uncommon or go unnoticed by patients, especially POAG. Peripheral vision is lost first and gradually progresses to central vision loss. Early complaints may be missing steps (loss of inferior visual field), missing portion of words while reading, or difficulty driving. PACG, specifically acute ACG, patients present with an extreme headache with distorted vision, severe eye pain, eye redness, vomiting, and halos around light. Hand movement can be detected and will experience pain on eye movement. Pupils are mid-dilated and non-reactive in acute ACG.

Diagnosis

Patients with an abnormal fundus examination and/or risk factors for glaucoma should be examined by an ophthalmologist or optometrist. The appearance of the optic nerve demonstrates the characteristic cupping found in glaucoma and should be visible on a fundus examination by the primary physician. Typically, a cup that is fifty-percent of the vertical disc diameter is indicative of glaucoma, but presence of cupping is not the sole diagnostic tool.⁷³ The funduscopy exam may also display thinning, pitching and/or notching of rim, fiber layer hemorrhage, vertical elongation of the cup, increased disc to cup ratio, and quick angulations of exiting blood vessels. The gonioscope is used to measure the iridocorneal angle and Goldmann applanation tonometry measures the IOP (assumes average corneal thickness). The Goldmann applanation may underestimate IOP if corneal thickness of a patient is lower than average. An IOP measurement above 23-24 mmHg requires at the least another measurement or follow-up. A pressure above 40 mmHg is considered an emergency. PACG typically presents as a cloudy cornea and ciliary flush. Slit-lamp findings include corneal edema, narrow anterior chamber, synechiae (iris adhering to cornea or lens), and irregular pupil shape or function. Functional changes occur prior to structural changes, so visual field deficits may be present before the optic nerve head displays degeneration.⁷⁴ Visual field deficits can also be applied to diagnose glaucoma using automated perimetry technologies or brain computer interface.⁷⁵ Newer technologies are being applied such as Optical coherence tomography, OCT, that detects certain features of the optic nerve head such as retinal nerve fiber and ganglion cell analysis.⁷⁶ Diagnosis is determined by funduscopy, visual field, OCT, corneal thickness, and gonioscopy.

Treatment

Vision loss due to glaucoma is irreversible due to the inability to regenerate optic nerve loss. The main treatment is to decrease IOP, including normal tension glaucoma. Treatment for acute ACG is time sensitive because significant damage can occur in an hour. Alpha-agonists, carbonic anhydrase inhibitors, miotic agents, rho kinase inhibitors, prostaglandin analogs or beta-blockers are the most common drugs and is administered topically with passive eyelid closure. Medical therapy is the primary treatment unless ineffective at controlling IOP or preventing progression. Microinvasive glaucoma surgery (MIGS) is a new alternative to topical medication as it is associated with few complications, particularly when compared to topical medications. MIGS does not lower IOP drastically; however, takes the place of a topical medication that requires patient compliance and associated with adverse consequences.³⁸ MIGS is a collection of procedures to control aqueous humor outflow with the insertion of an implant or surgical manipulation for those with mild to moderate glaucoma. Different MIGS exist depending on mechanism of action to control aqueous humor outflow. MIGS is typically done at the same time as cataract surgery.^{38,39} Progression is common due to the high costs and difficulty for older patients to follow the regiment. Patients at increased risk of progression are those diagnosed at an older age at baseline and higher IOP at baseline, access to care, initial vision worse than 20/40, and thinner corneal thickness.^{58,77} Vision loss is irreversible, so prevention is paramount. The majority of patients diagnosed with glaucoma will not go blind if treated. Patient compliance with treatment is crucial to prognosis.

Surgery is performed if medication is ineffective or severe vision loss occurs. Surgical options include laser trabeculoplasty, argon or selective, laser peripheral iridotomy or microinvasive glaucoma surgery (MIGS). Both laser trabeculoplasty options increase permeability of the trabecular meshwork. Argon laser trabeculoplasty is considered sooner in those with pseudoexfoliation or pigmentary glaucoma. Iridotomy is the surgical option for acute ACG. Trabeculectomy is considered if other options have failed to control IOP. It creates a hole in the iris allowing passage of the aqueous humor past the papillary block or damaged trabecular meshwork. Gene therapy, stem cell transplantation, and other neuroprotective and regenerative treatments are emerging to hopefully reverse optic neuropathy.⁷⁸ Regarding secondary glaucoma's, the underlying cause should be treated in conjunction with lowering IOP.

Age-Related Macular Degeneration

Overview

Age-Related Macular Degeneration (AMD) is the leading cause of legal adult blindness and vision impairment. AMD is the decay of a specific region of the retina known as the macula. The macula has the highest density of cones hence is responsible for central vision. Central vision is necessary for daily activities such as driving, reading, recognizing faces, watching TV, etc.⁷⁹ Vision loss due to AMD is irreversible. There are two pathologic types: non-exudative (dry) and exudative (wet) AMD. Dry AMD compromises ninety-percent of all cases and is characterized by drusen deposits in the retinal pigment epithelium, RPE, and Bruch's membrane. Drusen deposits are the earliest sign of AMD and are composed of vitronectin, amyloid P, apolipoprotein

E, and amyloid β .⁸⁰ Advanced dry AMD, referred to as geographic atrophy, is characterized by the decay of the retina, specifically the RPE cells and area other than the macula. Wet AMD is the more advanced form and compromising ten-percent of all cases.⁸¹ Wet AMD is the primary cause of severe vision loss observed in AMD. Exudative AMD is characterized by the formation of new blood vessels on the macula, also known as choroidal neovascularization. The pattern of neovascularization can be categorized into classic, occult, or fibrous lesions. Classic has well-defined borders with more leakage of fluid and occult has indistinct borders with less leakage of fluid. AMD is difficult to prevent and progression and overall prevention of vision loss. Geographic atrophy does not have an effective treatment, some new treatment options are in clinical trials. Wet AMD can be treated with anti-VEGF injections.

Epidemiology

An estimated 2.95 million Americans will be affected by AMD by 2020.⁷⁹ AMD is the leading cause of blindness in white persons, responsible for fifty-four percent of blindness in white persons.^{81,82} The prevalence rates of AMD ranged from 2.4-5.4% in the US population with the highest rate in white and Asian persons and lowest in Black persons. Early AMD prevalence rates increase up to approximately 16% in white and Asian persons of 75 years of age and older. Late AMD has a prevalence rate of 0.3-1% in all racial/ethnic groups.^{82,83,84,85,86} The disease is age-specific, disproportionately affecting those seventy-five years of age and older. Some studies have found women are more than twice as likely to develop AMD,⁸³ though some studies have not found a significant difference.⁸⁷ A predicated increase in prevalence is expected in 2050 but may be mitigated with current and new treatment options.⁸⁸

Risk Factors

Age-related macular degeneration is associated with a combination of genetic and environmental risk factors.^{79,89} Modifiable risk factors include smoking,^{90,91} increased body mass index, lower level of physical activity, and low antioxidant intake. Those 75 years of age and older are more prone to develop AMD. A diastolic pressure greater than 95 mmHg and those prescribed anti-hypertensive medication are more likely to develop wet AMD. Cardiovascular disease and UV radiation are risk factors.^{92,93} A history of AMD within a family is indicative of developing AMD.^{94,95,96}

Pathogenesis

Vision loss occurs when the photoreceptor cells (vision cells) die due to degeneration of the RPE or the effects of choroidal neovascularization. Degeneration may be due to oxidative stress and/or inflammation of the RPE and Bruch's membrane.

Dry AMD is characterized by the formation of drusen deposits in the RPE and Bruch's membrane and progressive loss of the RPE. Abnormalities of Bruch's membrane, inflammation, aging, oxidative stress, and chronic infection may all contribute to the development of AMD. RPE and photoreceptor death could be caused by ischemia due to insufficient blood flow through Bruch's membrane and choroid that differentially affects the macula.⁹⁷ The decline in perfusion may be due to age-related tissue degradation, hypertension, or diet-related effects on the

vasculature of the choroid.⁹⁷ Production of reactive oxygen species, ROS, induces oxidative stress and is related to smoking, high fat diet, aging, and genetic factors.^{90,99,100,101,102} Defects in mitochondria degradation may also occur and be associated with early stages of AMD, specifically regarding dysfunctional mitochondria.¹⁰³ Complement dysregulation occurs via the inappropriate activation of the complement cascade that may lead to inflammation, opsonization, phagocytosis, and cell death through the membrane attack complex.¹⁰⁴ Risk alleles complement factor H, CFH, and ARMS2, associated with regulation of the complement cascade can inappropriately activate the attack complex.^{103,105} Drusen deposits activating the inflammatory response may cause the complement dysregulation.¹⁰⁶ Inflammation is due to dysfunctional protein homeostasis (proteostasis) and the above mechanisms. Dysfunctional protein homeostasis (proteostasis) by inappropriate protein degradation may lead to chronic inflammation and ultimately AMD.^{102,105}

Vascular endothelial growth factor, VEGF, is the primary cause of CNV. VEGF promotes the growth of new blood vessels to counteract the lack of perfusion which inadvertently causes the loss of photoreceptors cells. This is the primary target for treatment of exudative AMD.

Signs and Symptoms

Early AMD is often asymptomatic with early complaints of gradual loss of vision in one or both eyes. Those with AMD experience central vision loss and is commonly reported as difficulty reading, driving, and facial recognition. Faces often appear blurred or distorted, difficulty recognizing identity, emotional states, and facial expressions to those with AMD. The effects of vision loss are detrimental to quality life apparent in increased incidence of traumatic hip fractures and depression in those with AMD.¹⁰⁷ Central vision loss, specifically high contrast visual acuity and contrast sensitivity are associated with vision related quality of life (VRQoL). Wet AMD may present with acute central vision loss and metamorphopsia. Metamorphopsia is distorted vision when looking at a grid of straight lines, with some lines appearing wavy and some appear blank; commonly seen when looking at window blinds or using the Amsler grid.¹⁰⁸

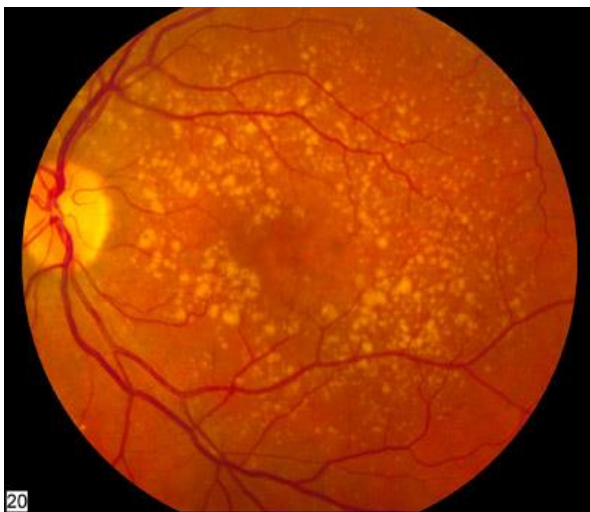

Figure 8: Fundus image of the intermediate stage of AMD. Drusen deposits are visible as the yellow circles on the retina.¹⁰⁹

Diagnosis

The primary care physician is often the first to hear the complaint of vision disturbance. Ophthalmic evaluation is necessary to diagnosis and differentiate dry and wet AMD. Nonexudative AMD will display drusen deposits on dilated eye examination. Five or more and at least 63 μm drusen deposits are typically present. Geographic atrophy may present as round or oval patches of depigmentation. Increased pigmentation with RPE mottling may also be present. A dilated eye exam displaying exudative AMD reveals subretinal fluid or hemorrhage. CNV appears as grayish-green discoloration of the macula and a fluorescein dye retinal angiography is necessary. Treatment is influenced by the specific results of the fluorescein dye retinal angiography.¹¹⁰ Optical coherence tomography, OCT, produces high-resolution images of the retina that shows retinal edema and subretinal fluid. Fundus autofluorescence can be used to stage and track the progression of geographic atrophy.

Treatment

Nonexudative AMD progression can be delayed by lifestyle changes, such as an addition of antioxidant vitamins through a healthy diet or supplement.^{103,111} This effect is only observed in those with moderate or advanced AMD receiving high levels of zinc and antioxidant supplementation.¹¹² Genotyping of risk alleles does not alter treatment options.¹⁰³ Vision loss may not be substantial if the fovea is not affected by geographic atrophy.¹¹⁰ The projected number of cases in 2050 is 25% lower in antioxidant-receiving scenarios.⁸⁸ There is not an effective treatment to prevent the onset or progression of geographic atrophy. Ineffective or unproven therapies include: laser therapy,¹¹³ statin therapy,¹¹⁴ and stem cell therapy.¹¹⁵

Exudative AMD is targeted with VEGF inhibitor, vascular endothelial growth factor, injections. Anti-VEGF drugs are bevacizumab, Avastin®, ranibizumab, Lucentis®, or aflibercept, not typically used in the United States. Periodic injections help prevent new formation of blood vessels on the choroid. A continuous treatment regimen is associated with better visual outcomes compared to treatment as needed.¹¹⁶ Risk of a systemic serious adverse events was estimated at 22.2% with ranibizumab and with bevacizumab of 24%. Overall not a significant difference in risk between the two drugs. Bevacizumab (Avastin®) and ranibizumab (Lucentis®) administered monthly gained 8.0 and 8.5 letters, respectively.¹¹⁷ Research into future therapies to prevent progression of vision loss is still needed. An estimated moderate vision loss occurs 6.0% and severe vision loss in 5.4% in persons with AMD during 10-year period.¹⁰⁷ Photodynamic therapy, PDT, is recommended for patients who cannot be treated with VEGF inhibitor injections. PDT involves the injection of a dye prior to photo-activating laser that targets neovascularization.¹¹⁸ Zinc with antioxidant supplements is indicated for those with wet AMD.¹¹² No effective treatment for geographic atrophy exists, but clinical trials are currently in the process.¹¹⁹

Once vision loss occurs, patients should be referred to a low vision specialist and visual rehabilitation centers and using a variety of visual aids. Closer-circuit visual training, CCVT, and eccentric training can help improve performance in daily activities such as reading, cooking, shopping. CCVT, which magnifies images electronically, is associated with a greater increase in

reading speed and more complex activities. Eccentric visual training is the process of looking slightly away from the subject to use peripheral vision rather than central vision.¹²⁰

Diabetic Retinopathy

Overview

Diabetic Retinopathy (DR) occurs when chronically elevated glucose levels damage the blood vessels in the retina and is associated with Type I, Type II, and gestational diabetes. Vision loss associated with DR is due to leakage and/or hemorrhage of blood vessel and is the leading cause of incident blindness in those 20-74 years of age.¹²¹ Diabetic Retinopathy is present in about 35% of all diagnosed diabetic patients and almost all diabetic patients will develop some form of retinopathy within 10-15 years of diagnosis. Vision loss typically occurs due to macular edema, hemorrhage from new blood vessels, retinal detachment, neovascular glaucoma. The presence of this disease may indicate micro-circulatory dysfunction elsewhere in the body. There are two types of DR with varying stages: non-proliferative, NPDR, and proliferative, PDR. NPDR is characterized by retinal vessels microaneurysms and retinal hemorrhages. NPDR is divided into 3 stages that indicates the risk of progression and treatment strategies. PDR is characterized by neovascularization from the optic disc and/or retinal vessels that can lead to vitreous hemorrhage, subsequent scarring, and tractional retinal detachment. Macula edema is due to the leakage of fluid and retinal thickening, specifically at the macula: can occur at any stage of DR. Early detection of DR is essential to prevent severe vision loss due to inability to reverse damage caused. DR is considered a preventable cause of blindness.^{121,122,123,124}

Epidemiology

Studies estimate that 28.5–40.3 % of patients with type 2 diabetes have DR, and 4.4–8.2 % of them have vision threatening diabetic retinopathy.^{123,125,126} Type I diabetics are more likely to develop DR, present in 75-82%, and vision threatening DR is present in approximately 31%. Prevalence of diabetic retinopathy and diabetic macular edema was significantly higher in blacks and Hispanics compared to whites at approximately 39%, 34%, and 26%, respectively.^{127,128} Incidence of DR in a community setting is estimated to be 18.8-28%.^{129,130,131} Retinopathy progression over a 5-year period is approximately 26% and progression to PDR was approximately 4%.¹³² The incidence and progression of diabetic retinopathy seems to be declining, possible due to current intensive glycemic and blood pressure control.^{123,124,133}

Risk Factors

Risk of diabetic retinopathy increases as duration of diabetes increases.^{134,135,136} Type I may be at an increased risk, especially with a history of smoking.^{127,137} Poor glycemic control, measured by elevated glycosylate hemoglobin HbA1c levels, leads to the development of DR. Higher diastolic blood pressure, poorly controlled blood pressure,¹³⁸ and high levels of blood-lipid levels are associated with DR.¹³⁹ Smoking,¹³⁷ cardiovascular disease,¹⁴⁰ higher body mass index,¹³⁵ and sleep disturbances place those with diabetes at an increased risk. Sleep

disturbances include: obstructive sleep apnoea sleep deprivation, excessive daytime sleepiness, and excessive sleep duration.^{141,142}

Pathogenesis

The disease process begins as NPDR, characterized by increased capillary permeability, microaneurysms, hemorrhages, exudates, macular ischemia, and macular edema. As the disease progresses, new blood vessels form to counteract retinal ischemia. Chronically elevated glucose levels damage the tiny blood vessels within the retina, specifically fundus vessels, which cause them to leak fluid, dilate, or rupture. Hyperglycemia damages all retinal cells including vascular, neurons, and glial cells.¹⁴³ Intensive insulin treatment that obtains a mean glycosylated hemoglobin level lower than other treatment options, reducing the incidence of new cases of DR by approximately 76%.^{144,145} Chronic hyperglycemia causes three main mechanisms that induce retinal vascular injury: hormonal, biochemical, and hemodynamic. Hormonal mechanism. Increased sorbitol production and glycosylation, breakdown of glucose, associated with increase in glucose can lead to increased oxidative stress.^{146,147} An increase in retinal blood flow is initiated by hyperglycemia and induces sheer stress on retinal blood vessels that may lead to macular edema.^{148,149} Before any clinical signs are observed, alterations in retinal blood flow have been observed and HbA1c is a determinant factor of angiogenic cytokines such as FGF-1, helps maintain vascular tone, and vascular endothelial growth factor (VEGF).¹⁵⁰ The release of growth factors, vascular endothelial growth factor (VEGF), IGF-1, and platelet-derived growth factor (PDGF) is initiated by retinal ischemia. Additional pathways have been proposed that cause retinal damage such as the polyol pathway flux, activation of diacylglycerol- (DAG-)PKC pathway, activation of the renin-angiotensin-aldosterone system (RAAS), and inflammation.¹⁵¹ The formation of new blood vessels and ischemia on the vitreous surface may lead to chronic inflammation. Inflammation may lead to leakage from dilated hyperpermeable blood vessels causing the breakdown of the retinal-blood barrier allowing the entry of lipid-protein into the retina.¹⁵² Elevated carbonic anhydrase levels are associated with hyperpermeable vessels.¹⁵³ Characteristic lesions and exudates are seen as a result of the inflammation process. The complete pathogenesis pathway of diabetic retinopathy is continuing to be discovered.

Signs and Symptoms

Non-proliferative diabetic retinopathy can be asymptomatic in the initial stages. Floaters, blurred visions, periods of decreased vision, distortion, flashes of light (photopsia) are presenting features of DR.¹⁵⁴ Vitreous hemorrhage typically causes floaters. Macular edema is the main cause of blurring vision. Clinical signs include capillary microaneurysms, dot and blot retinal hemorrhages, hard exudates, venous loops and beading, and cotton wool spots (soft exudates). Rupture of microaneurysms produces dot and blot retinal hemorrhages. Hard exudates suggest chronic edema and venous loops and beading are predictive of progression. Clinical signs of proliferative diabetic retinopathy include vitreous hemorrhages, fibrovascular tissue proliferation, and traction retinal detachment.¹³⁹

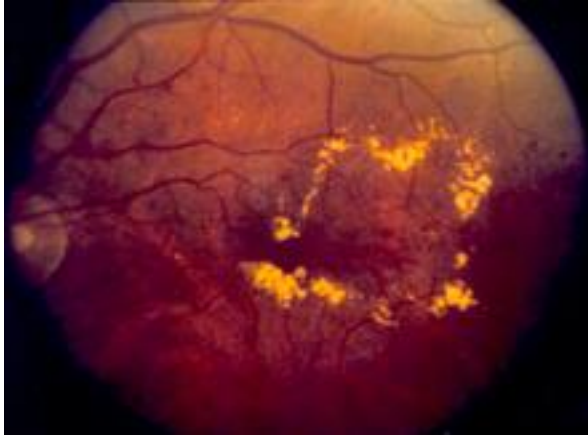


Figure 9: Fundus image displaying macular edema, a common clinical finding in diabetic retinopathy. May cause blurred/distorted vision ¹⁵⁵

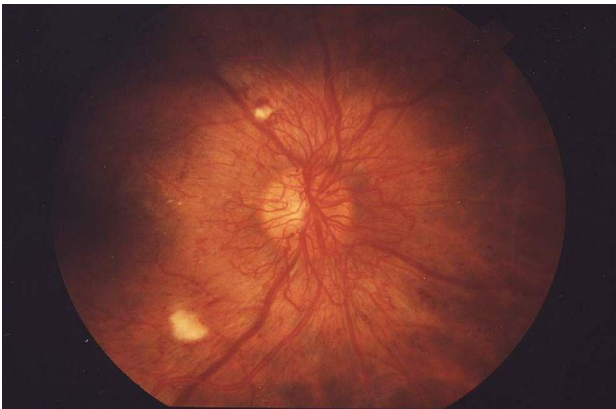

Figure 10: Fundus image of proliferative retinopathy. The formation of new blood vessels are visible around the optic disc. ¹⁵⁶

Diagnosis

Fasting glucose and hemoglobin A1c values are obtained along with fundoscopy exam, fluorescein angiography, optical coherence tomography (OCT), and B-scan ultrasonography to aid in diagnosis. Fluorescein angiography is used to document leaky or non-perfusing blood vessels. Dot and blot hemorrhages can be distinguished from microaneurysms. New blood vessels are categorized according to presence, location, severity, and hemorrhagic activity. OCT generates an image of the retina that displays retinal thickness and swelling. Macular edema is best visualized with OCT and fluorescein angiography. B-scan ultrasonography is useful to detect vitreous hemorrhage. Macular edema presents with yellow exudates, profuse leakage, and thickened macula. ¹³⁹

Treatment

Proper treatment and screening can hopefully prevent vision loss. Intensive glycemic control, blood pressure control, and serum lipid levels is beneficial for the prevention and progression of DR. ¹⁵⁷ Intensive insulin therapy can cause a short-term worsening of diabetic retinopathy as insulin upregulates expression of VEGF and IGF-1. The long-term effects of tightly controlled glycemic control outweighs the initial worsening of DR due to insulin. ¹⁵⁸ Hemoglobin A1c levels are recommended to be kept lower than or equal to 7%. The American Diabetes Association recommends systolic and diastolic pressures to be kept under 140 mmHg and 90 mmHg, respectively. ¹⁵⁷ Lipid-lowering therapy is not proven to prevent DR. ¹⁵⁹

Mild and moderate NPDR is typically not treated due to lack of vision loss. Macular edema, macular edema with NPDR, and PDR are treated with laser photocoagulation therapy and anti-VEGF agents. Laser photocoagulation therapy is effective in preserving vision for patients with high-risk or severe PDR without macular edema. In diabetics with severe or very-severe NPDR with a high risk of progression, early photocoagulation is beneficial prior to vision loss. ^{160,161} This treatment option is more durable and does not require multiple follow-up injection as in anti-VEGF treatment. Not recommended for eyes in the mild or moderate stage due to adverse effects of photocoagulation outweigh the benefits. Anti-VEGF drugs have been approved by the FDA to treat DR for compliant patients who are typically high-risk and severe proliferative DR with macular edema. Anti-VEGF agents are injected into the vitreous cavity using a needle and is short-term lasting 4 to 6 weeks. Continuous anti-VEGF injections rather than laser photocoagulation can be more effective in treating macular edema. Cessation of treatment, progression and/or recurrence can occur. ¹⁶² Vitrectomy is indicated if vitreous hemorrhage cannot be cleared or prevents photocoagulation, or tractional detachment involving the macula. Vitrectomy is the removal of the vitreous humor to allow better visualization of the retina, remove opacities, and release traction to reverse a detachment. ¹⁶³ Progression of DR can be prevented, but risk of progression increases with increased severity. One-year risk of progression to PDR for mild, moderate, and severe are 5%, 15%, and 52-75%, respectively. ¹²² A 25-year cumulative incidence rate of progression of DR was 83%, incidence of PDR 42%, including all age groups ¹⁶⁴ Women with diabetes are at a high-risk for progression of DR with poor glycemic control; however, this is not associated with long-term risk of progression. ¹⁶⁵

Keratoconus, Pellucid Marginal Degeneration, & Post-Surgery Corneal Ectasia

Overview

Keratoconus (KC), pellucid marginal degeneration (PMD), and post-surgery corneal ectasia are all non-inflammatory corneal ectasia disorders characterized by bulging and protruding of the cornea. Keratoconus is a non-inflammatory disorder characterized by a thinning and cone-shaped protrusion of the cornea. Presents as decreased visual acuity and frequent corrective lens changes due to progressive myopia, near-sightedness, and irregular astigmatism. Pellucid marginal degeneration is a slow degenerative disorder that commonly targets the inferior peripheral cornea and forms a crescent shape. It is commonly mistaken for Keratoconus. Pellucid marginal degeneration typically presents later in life and progresses slower than keratoconus.¹⁶⁶ Both diseases can present together, are bilateral, and eyes are commonly seen with both.¹⁶⁷ Post-surgery corneal ectasia is rare and may occur after LASIK.

Epidemiology

Corneal ectasia disorders are relatively rare. Incidence rate for keratoconus varies from 2 per 100,000 to 1 in 7,500. The prevalence rate is between 54 per 100,000 to 265 per 100,000. The occurrence of keratoconus is age specific with appearance at puberty or early-adulthood.^{168,169} There is no difference between incidence or prevalence rate between genders. A higher prevalence may be found in Asians, blacks, and Latinos than whites, but one study found confounding evidence.^{170,171} PMD is a rare disease that is more common in males. It affects all ethnicities and demonstrates no geographical predisposition.¹⁷² Post-surgery corneal ectasia occurs after 0.04-0.6% LASIK surgeries. LASIK and photorefractive keratectomy surgery accounts for 96% and 4% of secondary ectasia cases.¹⁷³

Risk Factors

Systemic disorders such as Down syndrome, Ehlers-Danlos syndrome, and osteogenesis imperfecta are associated with an increased risk of Keratoconus. Eye rubbing and contact lens, especially rigid lens, are associated with an increase in occurrence of KC.^{174,175,176} Atopic disease including allergies, asthma, eczema, and hay fever may predispose persons to developing KC.^{176,177} The prevalence in first-degree relatives with KC is 3.4% compared to the general population of 0.23-0.05% indicates a family history may be a significant risk factor.¹⁷⁸ A family history is also a significant risk factor for PMD.¹⁷⁹ Risk factors for post-surgery corneal ectasia include abnormal pre-surgery topography, younger age, and high myopia.¹⁸⁰ Abnormal pre-surgery topography may be a low residual stroma bed thickness and poor pre-surgery corneal thickness.^{180,181,182}

Pathogenesis

Keratoconus is due to unknown etiology, but protrusion of the cornea is most likely due to the increased intraocular pressure on the thinner portion of the cornea. Patients with KC have a

decrease in collagen content of the cornea which is most likely due to a multifactorial, multigenic disorder.¹⁸³ The etiology of the thinning of the cornea and decrease in collagen content is unclear. Reduced protein synthesis or increased degradation implicated in a family history may cause the changes in the molecular changes.¹⁸⁴ The pathophysiology of PMD is most likely similar to Keratoconus. Post-surgery corneal ectasia may be due to a lack of corneal wound healing that causes the cornea to bulge, predisposition to disease process that causes corneal bulging, residual bed is thin pre-surgery, or overtreatment causing instability of the cornea.¹⁸¹ The corneal ectasia disorders may be clinical presentations of the same disease.

Signs and Symptoms

Keratoconus patients typically present with asymmetric visual complaints as one eye may progress faster than the other. Difficulty correcting vision due to progressive myopia and astigmatism. Munson's sign is a v-shaped indentation of the lower eye-lid when gazing down. Corneal hydrops occurs in 3% of patients and presents as photophobia, sensitivity to light, and sudden painful decrease in visual acuity. Pellucid Marginal Degeneration patients complain of a gradual progressive loss in visual acuity. Astigmatism is irregular and against-the-rule-astigmatism.^{166,185} Corneal hydrops and acute corneal perforation are less common in PMD patients.¹⁶⁷ Post-surgery corneal ectasia have a history of LASIK or photorefractive keratectomy surgery.¹⁸⁰

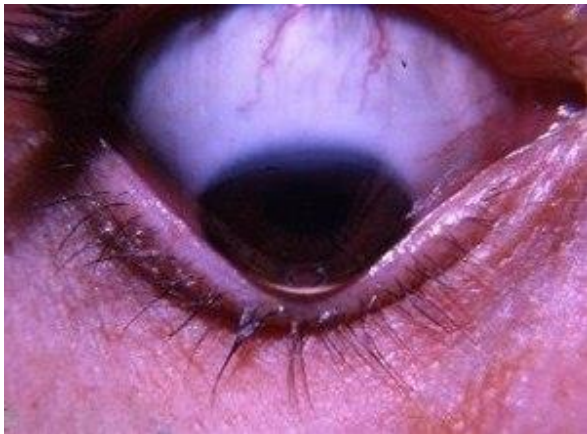

Figure 11: Keratoconus cornea displaying Munson's sign¹⁸⁶

Diagnosis

Diagnosed by history and clinical examination. The cornea may appear normal with slit-lamp examination. Slit-lamp may demonstrate Fleisher ring, Vogt striae, corneal scarring, and/or prominent corneal nerves. Fleisher ring is a brown-colored staining around the base of the cone of the cornea. Vogt striae are vertical stress lines in the thinnest portion of the cornea and disappear with gentle pressure. Corneal scarring may appear as central and inferior paracentral thinning.¹⁷⁶ Prominent corneal nerves should prompt further examination. PMD presents similarly to KC using slit-lamp exam, particularly in later stages of the diseases.¹⁸⁷ Retinoscopy may demonstrate a scissoring reflex, a sign during early development where two light bands can be seen moving towards and away from each other. Corneal topography is useful for diagnosis,

but not examining progression. PMD may appear like a “butterfly”, “kissing doves”, or “crab-claw” using corneal topography.^{167, 187}

Distinguishing KC from PMD can be difficult. Keratoconus typically presents with signs and symptoms decades earlier in life than PMD. In PMD, the cornea is inferiorly displaced; however, when a keratoconus is also inferiorly displaced it is difficult to distinguish between the two disorders: this distinction is not always reliable.^{187, 188} PMD is characterized by a narrow, clear band of corneal thinning around 1 or 2 mm in width PMD which extends from the 4-o'clock position to the 8-o'clock position.¹⁶⁷ Corneal topography is the main exam to distinguish PMD from KC.¹⁸⁷

Treatment

Correction of vision due to corneal ectasia disorders is the paramount goal in treatment is primarily treated with spectacles and contact lens. Hybrid contact lens may be suitable for those intolerant to gas permeable contact lens. Correcting vision is typically more difficult for those with PMD.¹⁸⁹ Surgery is only for patients who have poor visual acuity with corrective lens, contact lens intolerability, and corneal hydrops. Collagen cross-linking is a prevention treatment for progression and prevention of surgery. Worse prognosis of disease is associated with younger age at onset of KC, corneal scarring, and worse visual acuity.^{175,190} Treatment options for KC, PMD, and post-surgery corneal ectasia are the same, but are indication may differ.

Surgical options include intrastromal corneal ring segments and keratoplasty. Intrastromal corneal ring segments is a reversible safe and effective insertion of an implant into the cornea to maintain a regular shape. Indicated for early keratoconus, PMD, and post-surgery corneal ectasia.^{191,192} A significant improvement in visual acuity is observed but no improvement in astigmatism.¹⁹¹ Keratoplasty, most commonly is the penetrating keratoplasty, is a corneal transplant and 10-15% of patients undergo a keratoplasty.^{190,193} Good visual and refractive outcomes with few complications have been observed.¹⁹⁴ Variations of penetrating keratoplasty with similar results are microkeratome-assisted lamellar keratoplasty and deep anterior lamellar keratoplasty (DALK). DALK is newer and more technically challenging but may have less complications and faster visual rehabilitation. If DALK experiences complications, surgery is upgraded to penetrating keratoplasty.^{195,196}

Collage cross-linking is accomplished using combined riboflavin and ultraviolet A irradiation (UVA) to increase cross-linking between corneal fibers to prevent progression of the KC and PMD. In a randomized, controlled multicenter study of Keratoconus patients, improvement in maximum keratometry value (corneal thickness), corrected and uncorrected visual acuity were observed.^{197,198} Collagen cross-linking is not recommended for KC patients with a minimum corneal thickness of 400 microns, maximal keratometry less than 60 D, and must have no other corneal diseases (particularly herpes infection).¹⁹⁹ Cross-linking may be done in conjunction with surgery.²⁰⁰

Hypertensive Retinopathy

Overview

Chronic systemic hypertension damages arteries within the retina that can lead to hypertensive retinopathy. Systemic conditions such as diabetic and hypertension affect the microvasculature and commonly appears as ocular changes. Presentation of retinopathy may be the first symptom of systemic hypertension and referral to an ophthalmologist is recommended. Hypertensive retinopathy is characterized into three stages: mild, moderate, and malignant.²⁰¹ Hypertensive retinopathy may also present in those with preeclampsia. Malignant hypertension causes other eye pathologies such as choroidopathy and neuropathy due to ischemia. Hypertensive choroidopathy is more commonly observed in younger patients with acute hypertension and is characterized by focal necrosis of choriocapillaris underlying the retinal pigment epithelium and outer retina. Choroidopathy manifests as yellow exudates referred to as Elshnig spots.²⁰² Pregnancy induced hypertension, preeclampsia and eclampsia, commonly causes fundus changes and can be used as an indicator for degree of treatment and severity of hypertension. Abnormal fundus findings in patients with preeclampsia may predict indicate impending eclampsia.²⁰³ Treatment for HR is best accomplished by lowering blood pressure or treating the secondary cause of HR.

Epidemiology

Hypertensive retinopathy is present in just over a quarter (29.4%) of those with hypertension. It affects those with hypertension in adults age 50 years and older and males (64.1% compared to 35.9% females). HR is observed in 3-14% of persons 40 years of age and older and according to the Beaver Dam Eye Study an incidence in those 43 years of age and older is 6-10%.²⁰⁴ End organ damage in organs besides the eye (organ damage caused by the circulatory system) is more commonly seen in those with hypertensive retinopathy.²⁰⁵ HR affects African Americans more than whites, most likely due to higher prevalence of hypertension and severity of hypertension.²⁰⁶

Risk Factors

Risk factors for hypertensive retinopathy include increased duration of hypertension, family history, smoking, increased blood pressure and plasma levels of endothelin-1.²⁰⁷ Increased risk of malignant hypertension is associated with younger age and African-American men.²⁰⁸

Pathogenesis

Hypertensive retinopathy occurs due to systemic elevated arterial blood pressure that damages the retinal blood vessels. As blood pressure increases, vasculature responds by vasoconstricting due to autoregulatory mechanisms. In a healthy individual, autoregulation maintains ocular blood flow through the following mechanism: the arterioles constrict with a rise in blood pressure and dilate with a drop-in blood pressure.²⁰⁹ Those with systemic elevated arterial blood pressure, experience a focal or generalized dilation and damage of the blood retinal barrier. Chronic

hypertension leads to the development of thickening of the intima layer of retinal vessels and hyperplasia of media wall. This is seen in focal arteriolar narrowing and arterio-venous nicking. The exudative stage occurs with the disruption of the blood retinal barrier, necrosis of smooth muscle and endothelial cells, exudation of lipids and blood, and retinal ischemia.²¹⁰ As the retinal-blood barrier degrades, cotton wool spots, edema, and retinal detachments occur. HR does not consistently follow this sequence of disease with signs of severe appearing prior to mild signs.²⁰¹ High blood pressure alone does not account for the pathogenesis of HR and may be due to oxidative damage,²¹¹ low-grade inflammation,²¹² and increased platelet activation.^{204,213}

Signs and Symptoms

Hypertensive retinopathy can be the presenting symptoms in those with asymptomatic hypertension. Symptoms typically occur in later stage of the disease. Patients may complain of blurred vision or visual field deficits.²¹⁴ Less common symptoms may include headache and light flashes.²¹⁵ Signs of HR may include focal retinal arteriolar narrowing, arterio-venous nicking, microaneurysms, cotton wool spots, hard exudates, retinal hemorrhages, retinal/macular edema, and retinal detachments. Generalized retinal arteriolar narrowing and arterio-venous nicking are indicative of chronic hypertension whereas microaneurysms, focal arteriolar narrowing, cotton wool spots, and hemorrhages are indicative of acute hypertension.²⁰⁴ Cotton wool spots, areas of fluffy white or irregular shaped spots that may cover blood vessels. Edema and retinal detachment may occur due to ischemic damage of the retinal pigment epithelium.

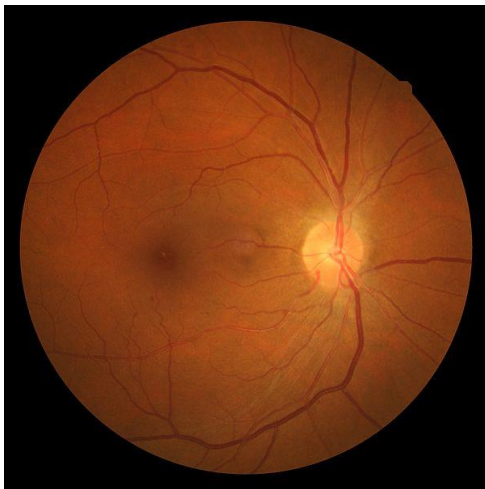

Figure 12: Fundus image of hypertensive retinopathy.²¹⁶

Diagnosis

Diagnosis of HR is accomplished using patient's history, fundoscopy exam, and possibly optical coherence tomography (OCT), and fluorescein angiography. A history positive for hypertension and family history may be indicative for HR. Fundoscopy exam is not a reliable for diagnosis and staging of hypertensive retinopathy; however, still plays an integral role in the identification of ocular changes related to retinopathy. HR is classified using a grading system. Grade 1 displays subtle broadening of the arteriolar light reflex, mild arteriolar narrowing (attenuation), particularly of small branches, and vein concealment. Grade 2 is associated with obvious

widening of the arteriolar light reflex and Salus signs (deflection of veins at arteriovenous crossings). Copper wiring of arterioles, banking of veins distal to arteriovenous crossings (Bonnet sign), tapering of veins on both sides of crossings (Gunn sign), and right-angled deflections of veins is associated with grade 3. Grade 4 displays grade 3 characteristics but displays silver-wiring of arterioles. Severe retinopathy (grade 3 and grade 4), or malignant hypertension, is relatively rare due to current hypertension treatment. (Patrick Scott, O.D., email communication)^{201, 217} Cotton wool spots appear lighter on fluorescein angiography and only seen three to six-week period before fading away.²¹⁸

Treatment

The main treatment for hypertensive retinopathy is controlling blood pressure. Adequate blood control can lead to retinopathy regression.²⁰⁴ Laser treatment or intravitreal injection of corticosteroids and anti-VEGF can be performed to help reverse vision loss due to retinal edema or retinal detachment. Optic neuropathy should not be treated by rapidly lowering blood pressure due to the possibility of worsening ischemia at the optic nerve. Autoregulation of retinal vessels leads to decreased perfusion to the optic nerve when blood pressure is dramatically lowered.²¹⁸ Malignant hypertension requires hospitalization and commonly parenteral drug therapy to lower blood pressure. Special consideration should be given to pregnant individuals with HR.²¹⁹ Fundus changes typically go back to normal, but permanent vision loss may be seen if irreversible damage was done to the blood vessels.²⁰⁸ Those with HR are at an increased risk of stroke, cardiovascular disease, and end organ damage (EOD).^{204, 217, 220} Patients with HR are at an increased risk of stroke as retinal vessels may be indicative of cerebral vasculature damage.²¹⁷ Increased retinal arteriolar narrowing was associated with an increased risk of coronary heart disease in women, not men.²⁰⁴

Retinoblastoma

Overview

Retinoblastoma (RB) is the most common cancer that occurs in the eye of pediatric patients, accounting for 4% of cancers in children under the age of fifteen and occurs in the womb up until the child is five years of age. Retinoblastoma is caused by a mutation in the retinoblastoma gene (RB1) located on chromosome 13. Retinoblastoma can occur bilaterally or unilaterally; hereditary RB typically occurs bilaterally. Proportion of bilateral cases and unilateral cases is stable at 27% and 72%, respectively and accounts for 2% of cancers in children under the age of fifteen.²²¹ Those with bilateral RB are at an increased risk of developing secondary cancers and also may develop trilateral retinoblastoma. This typically occurs in the pineal gland or midbrain. Current treatment has a survival rate of 97%.²²²

Epidemiology

Retinoblastoma occurs in 1 in 15,000 to 1 in 16,600 births and is the most common ocular cancer in children.²²³ There seems to be no difference in race or gender in respect to the incidence and prevalence of RB. Diagnosis occurs in children five years of age and younger, but some cases

have reported diagnosis at the age of 20.²²⁴ Pineal and non-pineal trilateral retinoblastoma occurs in 0.3%-3.8% of patients with retinoblastoma, higher prevalence rates occur in those with hereditary and bilateral RB.²²⁵

Risk Factors

A family history of germ-line RB mutation is a risk factor for RB; however, only 5% of patients have a positive family history.²²⁶

Pathogenesis

Retinoblastoma occurs most commonly due to a mutation in the RB1 gene, a nuclear protein that acts as a tumor suppressor and encoded on chromosome 13q14. The RB1 gene expresses a protein, pRB, that regulates cell division. pRB binds to the E2F transcription factor to suppress cell-proliferation, specifically prevents a cell from transitioning to the next phase of the cell cycle, G₁ to S phase.²²⁷ RB mutation can be germline or somatic, depending if the mutation is passed to the offspring. The two-hit hypothesis proposed by Alfred Knudson states the mechanism of a two mutation events behind the cause of Retinoblastoma.²²⁸ Hereditary RB1⁺/RB1⁻ inherit only one working copy of the RB1 gene from one of their parents (mom or dad) and undergo one mutation, “one hit”, that renders the RB1 gene non-functional, RB1⁻/RB1⁻. Germ-line mutations, passed to offspring, occur in about 40% of cases and commonly are bilateral cases. Germ-line mutations account for 20% of unilateral cases.²²⁹ In germ-line cases all the patient's cells contain only one working copy of the gene, therefore those with hereditary RB are predisposed to develop secondary cancers later in life due to only requiring one mutation.²²⁶ Non-hereditary RB are born with two working copies of the gene, RB1⁺/RB1⁺, undergo 2 mutations, “two hits”, that cause the RB1 gene to be non-functional within one somatic retinal cell. The two hit hypothesis is not as simple as once believed as different mutation affect the severity and phenotypic expression.²²⁷ The type of mutation affects the severity and phenotypic expression. A missense mutation is associated with unilateral RB, whereas frameshift and nonsense mutations are associated with bilateral RB.^{229,230}

The pathogenesis may be more complicated than previously believed. Not all cases of Retinoblastoma are due to a mutation in the RB gene, 2.7% of cases did not indicate a RB1 mutation, but an increase in the MYCN, an oncogene, or due to the human papilloma virus, HPV. MYCN promotes unregulated cell proliferation. These cases present with a different histology and an earlier stage of diagnosis than those with a RB1 mutation.²³¹ HPV has been implicated in the development of non-hereditary Retinoblastoma as it prevents pRB from binding to E2F leading to uncontrolled cell proliferation; however, this is mainly seen in developing countries.^{232,233}

Signs and Symptoms

Since Retinoblastoma primarily affects children five years of age and younger, parents commonly notice signs and symptoms of the disease. The most common sign of RB is leukocoria, a white pupil seen in the absence of red reflex in a picture. The white reflex is the tumor being reflected in the flash of a camera or in an fundoscopic exam. Second most common

sign is strabismus, occurring due to a tumor in one or both eyes causing a misalignment and eventual loss of central vision. Repetitive, uncontrolled eye movements, nystagmus, may be observed or a red, inflamed eye. Rarely heterochromia (different color pupils), hyphema (blood in anterior chamber of eye), glaucoma (increased intraocular pressure), or orbital cellulitis/inflammatory presentation may occur.²³⁴

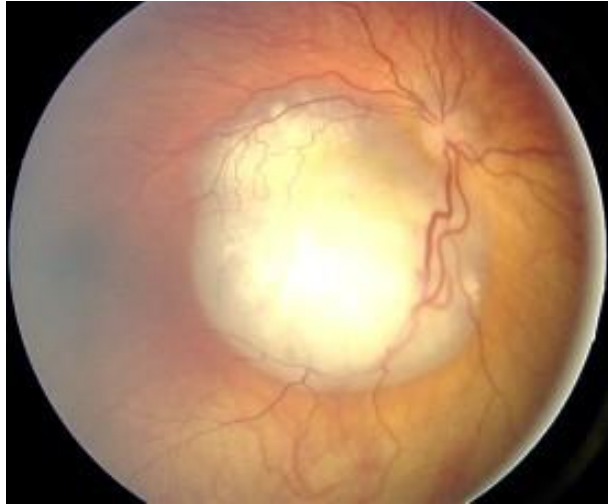


Figure 13: Fundus exam showing a Retinoblastoma tumor.²³⁵

Diagnosis

Diagnosis typically occurs before the age of 5, with the average age of bilateral at 13 months and unilateral at 24 months. Cases have been diagnosed past the age of 20, but very rare.²³⁶ If a parent or physician notices signs and symptoms associated with Retinoblastoma, referral to an ocular oncologist is indicated. A physical examination will be performed including ophthalmoscope examination under anesthesia (EUA), ocular ultrasonography, optical coherence tomography (OCT), and an MRI of the brain and orbits. The ocular ultrasonography and OCT typically occur during the EUA. The ocular ultrasonography may be performed prior to the EUA and detects calcification of the tumor, characteristic of RB.²²⁷ The OCT can be used for screening, detection, and during and after treatment of RB. The MRI detects metastasis to the optic nerve and presence of trilateral RB. Genetic testing is completed for every RB patient to detect germline mutations. If germline mutations are found, parents and sibling should be tested by a geneticist.^{237,238}

Once diagnosed, the tumor will be classified into one of five groups using the Intraocular Classification of Retinoblastoma (ICRB) or by International Intraocular classification of Retinoblastoma (IICR). The Philadelphia or St. Jude classifications may also be used for the stages of RB. A unified classification system has yet to be developed; the ICRB and IICR are the primary classification systems used throughout the world. The ICRB and IICR are classified into groups A-E according to size, location, and other features to predict response to treatment. Group A is very low-risk with a tumor less than 3 mm, confined to the retina, at least 3 mm from the fovea, 1.5 mm from the optic nerve, and no vitreous or subretinal seeding present. Group B

tumors are bigger than group A, characterized by subretinal fluid extending from the tumor but not extending 5 mm from the base of the tumor. Group C is moderate-risk displaying focal vitreous or subretinal seeding, discrete retinal tumors present, and only one quadrant of subretinal fluid present. The seeding must be local, fine, and limited to an area that may be treated with radioactive plaque. Group D is at high risk with diffuse greasy, extensive vitreous or subretinal seeding and/or massive, non-discrete endophytic or exophytic disease. The subretinal seeding may be plaque-like and may have greater than a quadrant of retinal detachment. The very high-risk is group E with eyes displaying one or more of the following: irreversible neovascular glaucoma, massive intraocular hemorrhage, aseptic orbital cellulitis, tumor anterior to anterior vitreous face, tumor touching the lens, diffuse infiltrating retinoblastoma and phthisis or pre-phthisis. Groups A-C were successfully salvaged in over 90% of eyes and group D, the globe was salvaged in approximately 47% of eyes. Group E eyes were enucleated immediately.²³⁹

Treatment

Current treatment of Retinoblastoma is effective with a 97% survival rate, with survival the primary goal followed by globe and vision preservation.^{222,240} If diagnosis is late in the disease or treatment is discontinued, prognosis is not promising with a high rate of metastasis and removal of the eye. The stage of the tumor at diagnosis determines the treatment plan with low-risk tumors treated focally and high risk treated aggressively. Group A is treated primarily with focal therapies as spot treatment of tumor and surrounding vasculature combined with systemic chemoreduction therapy.²⁴⁰ Focal therapies consist of laser therapy, thermotherapy, cryotherapy, and stereotactic conformal radiotherapy (SCR).²⁴¹ An argon laser is used to coagulate the blood supply to the tumor in laser therapy. A newer laser treatment is SCR as it delivers a more accurate laser treatment. Thermotherapy is performed under general anesthesia with an infrared radiation and is often paired with chemotherapy. Lasting regression was seen in 86% of tumors after thermotherapy.²⁴² A metal probe is cooled to very low temperatures to freeze the tumor cells for cryotherapy.²⁴³ Chemotherapy in combination with focal therapy is common for groups A-D; however, if treatment fails external beam radiation therapy, EBRT, or enucleation may be performed. EBRT is an older, outdated treatment associated with serious complications including: cataract, facial growth disturbance, optic neuropathy, and secondary malignancy.^{240,244} Group C and D globes commonly undergo systemic chemotherapy combined with focal therapy and/or intra-arterial chemotherapy. Removal of the eye globe is referred to as enucleation and is a life-preserving surgery at late stages of the disease. Once removed it is sent for pathologic evaluation to determine risk of spreading. An ocular prosthesis is fitted.²⁴⁰

Intra-arterial chemotherapy technique (IAC) is an effective treatment as the first-line and second-line of defense of RB used in combination with or as an alternative to systemic chemotherapy and focal therapy. IAC is associated with an increase of survival without enucleation.^{245,246,247} As primary treatment, 100% of globes treated as group A, B, and C were salvaged and 94% and 36% in group D and E, respectively. An estimated ocular event-free survival rate of 70-72% has been reported. As a secondary treatment, IAC has a 58-62% of a 2-year ocular event-free survival rate.^{248,249} Also, effective to resolve complete and partial retinal detachments. The temporary complications associated with IAC are transient eye-lid edema, blepharoptosis, and forehead hyperemia. Longer term complications seen in 2% or less of globes are vitreous hemorrhage, branch retinal artery obstruction, ophthalmic artery spasm with reperfusion,

ophthalmic artery obstruction, partial choroidal ischemia, and optic neuropathy. Stroke, death, or neurological complications have not been observed with IAC.^{246,248,249}

Fuch's Corneal Dystrophy

Overview

Fuch's Endothelial Corneal Dystrophy (FECD) is a bilateral, age-related disorder affecting the corneal endothelium that causes significant vision loss. It was first described by an Austrian ophthalmologist in 1910.²⁵⁰ It is the most common reason for corneal transplantation, accounting for 36% of the 47,000 corneal transplants in the United States.²⁵¹ FECD sub-divides into: early-onset around the age of 30 and late-onset around 50 years of age. Early-onset is rare and typically follows an autosomal dominant inheritance pattern. Late-onset has been observed as familial and non-familial cases. The most common clinical characterization of Fuch's dystrophy is into 4 stages. Stage 1 is characterized by corneal guttae period, with local thickening of the Descemet's membrane (DM), which is visible with corneal biomicroscopy. In stage 2 the number of corneal guttae increase and fuse together as they expand to the periphery. As the location of the corneal guttae expand throughout the DM, the density of the corneal endothelial cells decreases. The function of these cells is impaired and corneal stromal edema increases. As FECD progresses to stage 3, corneal stromal edema continues to worsen leading to the formation of epithelial and subepithelial bullae. These bullae can rupture which causes pain, photophobia, tearing, and increases the risk of infection. The final stage is due to long-term corneal stromal edema. This may lead to subepithelial connective tissue and can occur at the same time as corneal scarring and corneal neovascularization. The appearance of subepithelial connective tissue occurs with reduced corneal transparency. Corneal scarring and neovascularization also contribute to a significant decrease in visual acuity. The four stages may be observed in the same eye.²⁵²

Epidemiology

FECD affects 4% of the population 40 years of age and older. Women tend to be affected two to four times more than men. Late-onset FECD may be familial, as it is passed on to family.

Risk Factors

Risk factors associated with FECD are a family history and increasing age as late-onset is more common. Few studies have been completed to determine risk factors for FECD.²⁵³

Pathogenesis

The pathophysiology of Fuch's Endothelial Corneal Dystrophy is due to a combination of genetic and environmental factors. The cause of the increased deposition of extracellular matrix, ECM, and loss of corneal endothelial cells may be due to oxidative stress, abnormal apoptosis, inflammation, and epithelial-mesenchymal transition, EMT.²⁵² Fuch's dystrophy affects corneal endothelial cells (CEC). CEC function to maintain the cornea's transparency through sodium-

activated ATPase pumps. As functioning declines in FECD, the cornea begins to accumulate fluid.²⁵⁴ EMT, immune-response, and ECM related genes were found to be upregulated and inflammatory cytokines and visual perception-related genes were downregulated. The upregulation genes demonstrate an increased immune response in the corneal endothelium and Descemet's membrane. Downregulation of the inflammatory cytokine may induce monocytes to differentiate to dendritic cell maturation, fibrocyte differentiation characteristic of late-FECD.²⁵² The results of the altered expression of the genes causes the increased deposition of ECM and endothelial cells loss. Abnormal apoptosis may occur due to misfolded proteins causing rough endoplasmic stress or oxidative DNA damage leading to endothelial cell loss.^{255,256,257} Reactive oxygen species, ROS, are known to cause cell death and vascular endothelial dysfunction leading to cell loss.²⁵⁸ Abnormal deposition of the ECM, corneal guttae, may be due to EMT inducing genes causing excessive production of ECM proteins in corneal endothelial cells found in FECD patients.²⁵⁹ Genetic analysis has implicated specific mutations in the development of FECD; early-onset is associated with the COL8A2 gene and late onset is most likely an interaction between multiple genes.^{252,260} The COL8A2 gene that encodes for the collagen alpha-2 (VIII) chain, extracellular matrix protein, is implicated in familial and non-familial cases.²⁶¹ The disease typically follows an autosomal dominant inheritance pattern.²⁶⁰ The pathophysiology of FECD is complicated and further research is necessary.

Signs and Symptoms

Those with FECD complain of blurry vision. Their vision may be misty in the morning and will clear throughout the day. A feeling of a gritty or foreign body sensation, redness, pain, eye watering lasting for hours, and seeing halos around sources of light may occur in those with FECD. Poor recovery after cataract surgery or eye surgery may be indicative of FECD.²⁶²

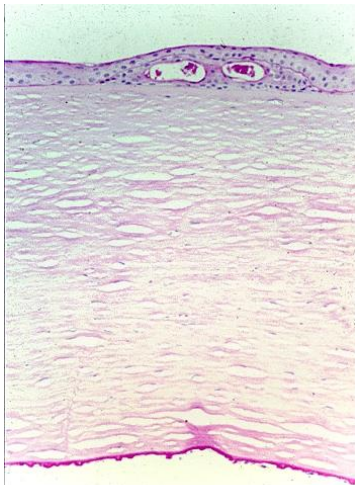


Figure 14: Light microscope of a cornea affected by Fuchs corneal dystrophy showing numerous excrescences on the posterior surface of the Descemet membrane (guttae). The presence of cysts may be observed beneath the basement membrane. Periodic acid-Schiff stain.²⁶³

Diagnosis

Diagnosis is done using slit-lamp examination and optic coherence tomography (OCT). Slit-lamp is primarily used in the diagnosis and initial assessment of FECD. Presence of corneal guttae is observed using specular microscopy or confocal microscopy. OCT is becoming more commonly used to trace the progression of the disease.^{262,264}

Treatment

Treatment for FECD is not necessary until the cornea becomes cloudy and vision is affected. Non-surgical treatment options include dehydrating agents such as 5% sodium chloride or use of a hair dryer. The goal is to dry out the cornea to clear vision. The hair dryer method is best done at arm-length and low-setting to avoid thermal injuring to the cornea. The purpose of the dehydrating agents and hair drying is to remove the fluid from the cornea that disrupts vision. An effective prevention is yet to be discovered due to lack of understanding of pathogenesis.

FECD is the leading cause of corneal transplant. Different variations of a keratoplasty may be performed to replace the cornea. The most popular procedure over the past 100 years is a penetrating keratoplasty, PK, which involves the replacement of the entire cornea. Recovery of visual acuity is slower compared to other surgical options. Endothelial keratoplasty (EK) is the replacement of the endothelial layer without affecting the anterior structure of the cornea. The Descemet membrane endothelial keratoplasty (DMEK) and Descemet stripping endothelial keratoplasty (DSEK) have similar 5-year survival rates, approximately 93%. DMEK had a significantly lower risk of immunologic rejection.²⁶⁵ DSEK patients experience an improvement in vision up to 5 years after surgery with more than half of eyes realizing acuity enhancement better than 20/25.²⁶⁶ Commonly those with FECD also have or will develop cataracts. If this patient undergoes cataract surgery, they will speed up the need for a corneal transplant as endothelial damage is common and FECD patients' corneas are predisposed to have a thinner corneal thickness. Future treatments may include human cultured endothelial cells to restore function to the cornea as the cornea cannot regenerate. This has been demonstrated in rabbit corneas and will continue to human trials.²⁶⁷

Herpes Zoster Ophthalmicus

Overview

Herpes Zoster Ophthalmicus (HZO), is a complication of the varicella zoster virus that causes shingles and chicken pox. It is the human virus type 3 and affects the first branch of the trigeminal nerve (V1), the ophthalmic region of the fifth cranial nerve.²⁶⁸ The trigeminal nerve innervates the eyelid, brow, forehead skin, and skin of the tip of the nose. Signs and symptoms can include a forehead rash and painful inflammation of the tissues surrounding the eye. The most common eye conditions with HZO are keratitis, conjunctivitis, and uveitis; however, the long-term complications can include glaucoma, cataract, corneal scarring, and PHN (postherpetic neuralgia).²⁶⁹ HZO is normally self-limiting but is treated with oral-antivirals and in combination with topical corticosteroids.

Epidemiology

The incidence of Herpes Zoster Ophthalmicus is approximately 2.2 per 1,000 to 3.4 per 1,000 in the general population. The incident rate does not seem to be affected by gender but does increase with age as older populations may be affected up to 10 per 1,000 persons.^{270,271} This disease presents in roughly 8-20% of those affected by the Herpes Zoster virus and reoccurs in approximately 6% of those affected.^{268,272} A trend in increasing rate of HZ eye involvement has been observed and does not seem to be connected to vaccination of the varicella zoster virus.^{273,274}

Risk Factors

Risk factors for Herpes Zoster Ophthalmicus include older age, average age of 63, emotional and physical stress, immunodeficiency, poor nutrition, HIV, and cancer.^{271,275} Therapies associated with cancer such as radiation therapy and chemotherapy, also are risk factors.²⁷¹ These risk factors mainly focus on the increased incidence of HZO and immunocompromised individuals.

Pathogenesis

The varicella zoster virus can first present as the chickenpox infection (can also be introduced in the vaccine, rarely). After the primary infection, the VCV can lay dormant for years and is replicated within regional lymph nodes. In the case of herpes zoster ophthalmicus, the virus lays dormant within the trigeminal nerve until a cell-mediated immune response reactivates the virus. When the virus is reactivated it typically only occurs on one nerve root on one side of the body, affecting one side of the face. T-cell mediated immunity may play a role in the reactivation of the virus, but further studies are needed.^{276,277,278} After reactivation the virus travels along the nerve and causes the associated signs and symptoms due to the local immune system response.^{271,279}

Signs and Symptoms

HZO may be divided into three phases: pre-eruptive, acute eruptive, and chronic phase. The pre-eruptive phase may be characterized by a burning, tingling, or shooting pain that may be accompanied by systemic viral symptoms such as a fever, malaise, fatigue, photophobia (sensitivity to light), and headache up to a week prior to the acute eruptive phase.^{271,279} A painful, pustular, vesicular rash and inflammation affecting the forehead and/or tissues surrounding the anterior and posterior eye characterizes the acute-eruptive phase of HZO. Hutchinson's sign is a classic sign of HZO that affects the skin of the tip of the nose and is prognostic for ocular inflammation, corneal sensory denervation, and sight-threatening complications.²⁸⁰ Eye involvement may be keratitis (most common), conjunctivitis, uveitis/iritis, and scleritis that may further complicate the infection.²⁷⁴ Eye-lid involvement typically appears as a macular rash and further acquire a secondary infection producing yellowish discharge. The acute-eruptive phase may last 10-15 days. Immunocompromised individuals may experience more serious complications including retinal detachment and acute retinal necrosis that may result in permanent vision loss. The chronic phase occurs after the rash subsides and is characterized by postherpetic neuralgia, PHN. This is the most common chronic complication in

HZO patients. PHN can last more than 30 days and is characterized by chronic severe neuropathic-type pain that may be accompanied by ocular manifestations that may cause a secondary infection.²⁷⁹

Diagnosis

A complete history should be obtained including a history of a primary VCV infection and vaccination records. If HZO is suspected a complete ophthalmic examination is indicated by an ophthalmologist. Vision tests, intraocular pressure, pupil reaction, and in-depth examination of the eye and surrounding tissue should be completed to document ocular involvement. Examination includes fluorescein staining of the cornea and a dilated funduscopy examination to document corneal and retinal involvement.^{271,279}

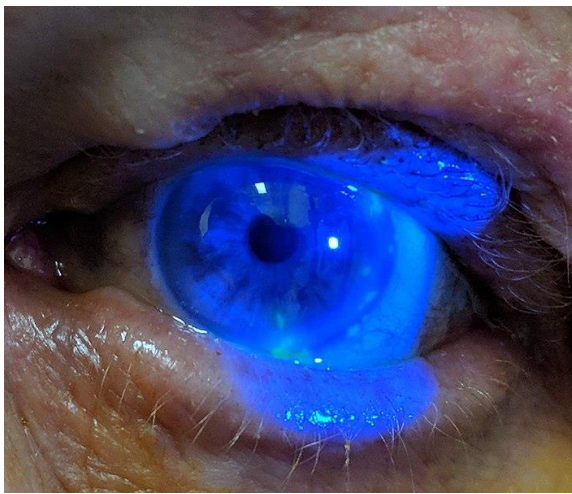


Figure 15: Fluorescein staining of the cornea using cobalt blue light.²⁸¹

Treatment

Vaccination is paramount to prevent HZ, HZO, and PHN infection. The recommended age to receive the shingles vaccination is 60 years of age and older.²⁸² HZO is a self-limiting infection; however, prompt treatment leads to a lower incidence of adverse effects and a shorter duration. Treatment varies depending on the degree of ocular involvement. Acyclovir is the most common oral anti-viral prescribed but valacyclovir or famciclovir have been shown to be equally effective to prevent virus replication. Hospitalization may be needed to administer intravenous acyclovir in immunocompromised patients or in those with sight-threatening complications. Topical corticosteroids reduce inflammatory response and control immune-associated keratitis and iritis.^{268,271,279,283,284}

Complications observed with HZO include PHN, retinal detachment, optic neuritis, and severe corneal involvement. Postherpetic neuralgia is characterized by persistent pain that continues after the rash has resolved and occurs in 21% of those with HZO. Older age and HZO with keratitis, conjunctivitis, or uveitis were found to be risk factors for PHN.²⁸⁵ An increased risk of stroke, 2-fold increase, and dementia, 2.9-fold increase, is associated with varicella zoster virus

due to negatively affected vasculature.²⁸⁶ A permanent decrease in visual acuity is observed in 6.6% of HZO and portion of this is due to the virus affecting the optic nerve resulting in optic neuritis.²⁸⁷

Amblyopia

Overview

Amblyopia, often referred to as lazy eye, is decreased vision due to abnormal development during infancy or childhood of one or both eyes. Amblyopia is defined as best-corrected visual acuity of 20/40 to 20/400 of one eye as the contralateral eye having a visual acuity of 20/40 or better.²⁸⁸ It is the most common cause of vision impairment in children. If vision is altered by strabismus, refractive error, or vision deprivation during the critical period for development of the vision centers of the brain, development will not occur properly resulting in Amblyopia. The critical period in development occurs when particular behavior, integration of binocular vision, is acquired which cannot be learned after this period.²⁸⁹ A dependence on the dominant eye will occur and the eyes will not coordinate. Coordination is necessary for binocular vision which is necessary for depth perception. Strabismus is a misalignment of the two eyes, as one eye is weaker than the other it is often not tracking with the stronger eye. The brain will be receiving signals from both eyes that differ slightly leading to the visual cortex not coordinating the two images. Refractive error may result in amblyopia as one eye with poor vision cannot contribute to the development of the visual cortex. Vision deprivation results in the most severe amblyopia and is due to congenital cataracts, ptosis, retinal detachment, or congenital corneal opacities. Treatment is time sensitive for proper development. Those with amblyopia are at an increased risk of permanent monocular vision impairment if subsequent trauma or disease affects the dominant eye.

Epidemiology

Amblyopia occurs in approximately 0.5- 3.5% of children 8 years of age and younger.^{290,291} Gender does not affect the rate of amblyopia. Amblyopia was found to occur in 2.6% of Hispanic/Latino children, 1.5% of African-American children, and 1.8% in Asian and non-Hispanic white children. Bilateral amblyopia is rare occurring in 0.4 to 0.12% of children.^{292,293,294} It is the cause of approximately 50% of cases, refractive error is responsible for approximately 15 to 20% cases, and deprivational is approximately 5% of cases.²⁹⁵

Risk Factors

Children with strabismus, refractive error, and congenital causes of vision deprivation place a child at risk of developing amblyopia.²⁸⁸ Those at risk to develop amblyopia are children born premature, small size for gestational age, a first-degree relative with amblyopia, and a neurodevelopmental delay.

Pathogenesis

Amblyopia due to strabismus occurs as the two foveae receives two distinct images and the visual cortex suppresses one image to avoid double vision (diplopia). Strabismus can be divided into convergent (esotropia, “crossed eyes”) or divergent (exotropia, “wall eyes”) strabismus depending on extrinsic eye muscles affected.²⁸⁹ As suppression occurs long-term, strabismus amblyopia develops as the weaker eye’s image is made “invisible” to avoid double vision or confusion. Amblyopia does not occur in all children with strabismus. Those with intermittent strabismus, the image is fused for a large portion of the time preventing the development of amblyopia. Those with alternate fixation, sometimes the right and sometimes the left eye, amblyopia does not develop in most children because one eye is not dominant.

Asymmetric refractive error (anisometropia) occurs due to an image presenting with different clarity at the fovea of both eyes. The eyes have unequal refractive error resulting in an image being focused on the fovea of one eye, but not the other. Anisometropia is most common in hyperopic eyes and still may occur in severe myopia. Severe uncorrected bilateral refractive error may result in ametropic or isoametropic amblyopia.

Deprivational amblyopia is caused by the distortion of images at the fovea that prevents the visual cortex from developing properly. Vision deprivation can be due to congenital cataracts, ptosis, retinal detachment, or congenital corneal opacities. Congenital cataracts can cause amblyopia due to decreased transparency of the lens causing severe refractive error. Ptosis is the falling or drooping of the upper eyelid that can block vision and amblyopia occurs in 18% of children with ptosis.^{296,297} Can occurs as the muscles holding up the eyelid become tired or congenital problem with the muscle, levator palpebrae.²⁹⁸ Deprivational amblyopia can result in permanent visual impairment if not treated early.

Signs and Symptoms

Amblyopia is asymptomatic in most children and detection relies on screening by screening programs by volunteers, parents, schools, or pediatricians. Children with amblyopia often squint, close one eye to see better and experience headaches, eyestrain and general vision impairment.

Diagnosis

Amblyopia is defined as best-corrected visual acuity of 20/40 to 20/400 of one eye as the contralateral eye having a visual acuity of 20/40 or better.²⁸⁸ Screening to detect amblyopia should be done for all children, specifically those 3 to 5 years of age.²⁹⁹ It is difficult to diagnosis children under the age of 3 due to lack of mature responses.^{295,297} Visual acuity screening is commonly accomplished using Lea symbol chart or the HOTV visual acuity tests. The Lea chart uses the symbols (heart, house, heart and circle) of illuminated objects to test monocular vision. HOTV utilizes the letters (H, O, T, and V).³⁰⁰ The tumbling E test may also be used but is difficult for young children.³⁰¹ Positive screening tests constitutes referral for ophthalmologist evaluation. Other screening options include photo screening and autorefraction. Photo screening is used to detect ocular defects that commonly cause amblyopia and can be

analyzed by an ophthalmologist, computer, or a reading center. Autorefraction, automated retinoscopy, detects refractive error in each eye.

Treatment

Untreated amblyopia can lead to permanent vision impairment through adulthood. Historically amblyopia was treated by placing an eye patch over the dominant eye to strengthen the use of the other. Amblyopia may be treated for short periods of time throughout the day with multiple methods: patching, binocular iPad games, and perceptual learning. Studies have demonstrated full-time occlusion therapy is equally effective as a 6-hour period occlusion. A 6-hour occlusion therapy is also equally effective as a 2-hour occlusion period. Best outcomes with treatment observed with patching is in younger children, as the age increases effectiveness decreases.³⁰² Surgery for strabismus caused amblyopia to alter the length of affected extraocular muscle is commonly performed to align the eyes.²⁸⁹ Perceptual learning relies on repeated practice of a visual task either monocular or simultaneously to both eyes and is associated with synaptic plasticity.³⁰³ Perceptual learning may improve crowded letter discrimination and contrast sensitivity.³⁰⁴ The criticism of perceptual learning focuses on the inability for the learning to be used for novel situations; however, is still a valid avenue to improve vision particularly in adults.³⁰² Dichoptic training presents stimuli to each eye independently to reverse binocular viewing to reprogram binocular vision integration. The patient's suppressed eye is presented with an image with a higher contrast to undo the suppression of the amblyopic eye. Dichoptic training is employed in binocular iPad applications, such as a Falling Block game or Dig Rush game (more stimulating game with a higher compliance). Short term vision improvement for a binocular iPad game is more beneficial than traditional patching, but long-term benefit has yet to be determined.^{302,305} One study found Dig Rush game to be ineffective in improving visual acuity 4 to 8 weeks post treatment.³⁰⁶

Retinitis Pigmentosa

Overview

Retinitis Pigmentosa (RP), also known as rod-cone dystrophy, compromises a group of inherited progressive retinal dystrophy disorders that primarily target photoreceptors and pigment epithelial function that may lead to blindness. RP is categorized into non-syndromic (only affecting eyes) and syndrome (systemic disorder). Inheritance patterns vary and are divided into three groups: dominant, recessive, and X-linked. Non-mendelian inheritance patterns are also observed, such as digenic inheritance, compound heterozygosity, maternal (mitochondrial) inheritance, or sporadic (only family member with a disease genotype). Interestingly, identical mutations may cause distinctly different clinical presentations or different diseases altogether.³⁰⁷ Common syndromic forms of RP are Usher syndrome and Bardet-Biedl syndrome. Usher syndrome presents with vision and hearing loss. Bardet-Biedl syndrome is characterized by postaxial polydactyl (additional digit on ulnar side of hand), central obesity, mental retardation, hypogonadism, and renal dysfunction.³⁰⁸ RP negatively affects quality of daily life as it affects daily activities such as cooking, driving, and self-grooming.³⁰⁹ Treatment options are available; however, RP is considered incurable.

Epidemiology

Retinitis pigmentosa is a relatively rare disorder; estimated to affect 1 in 4,000 persons and incidence of 0.79 in 100,000.^{310,311} Prevalence increases with age for both genders. Women with X-linked RP may present with RP later in life than other forms of the disorder.³¹¹ Non-syndromic Retinitis pigmentosa comprises over 65% of all cases in the United States. Of those non-syndromic cases are approximately 30% autosomal dominant, 20% autosomal recessive, 15% X-linked, 5% recessive early-onset, and 30% sporadic (random). Usher syndrome and Bardet-Biedl syndrome comprise 10% and 5% of all RP cases.³⁰⁷ Approximately 40% of mutations causing RP are yet to be identified. Only 60% of sporadic cases, unknown or absence of family history of disease, mutations have been identified.³¹²

Risk Factors

Since Retinitis Pigmentosa is a genetic disease, the mode of inheritance affects the risk of developing Retinitis Pigmentosa. Autosomal dominant and autosomal recessive with RP have a 50% and 25% chance of passing on RP to their children, respectively due to mendelian genetics. Those with family members affected have a decreased risk of developing RP as they age because diagnosis typically occurs approximately at 37 years of age.³¹³

Pathogenesis

Retinitis Pigmentosa is also known as rod-cone dystrophy because the degeneration begins in the peripheral rods and moves centrally to the cones. Rods and cones are photoreceptors located in the retina that capture light. Rods are necessary for dim, dark lighting and are found in the periphery of the retina. Cones are necessary for color-vision, bright light, and found in the center of the retina. Degeneration of the rods characteristic of RP can be caused by over 65 different genetic mutations.³¹⁴ A difficulty associated with the characterization and prognosis of RP is how one mutation can present with different signs and symptoms in different patients. The majority of identified RP genes only causes a small number of cases, except for RHO (Rhodopsin), USH2A (Usherin), and RPGR (RP GTPase regulator) genes together cause 30% of cases.³⁰⁷

Degeneration of the rods and followed by degeneration of the cones follows a predictable pattern according to the gene that is mutated. The cones do not degenerate due to the mutated gene, rather from the effects of the death of the rods. The timeline of rod and cone death associated with specific gene mutations may differ due to environmental and other genetic differences within an individual. The relationship of rods on cones survival requires further research but may be due to the following theories. Trophic support between rods and cones may play a role as a viability factor (two forms of RdCVF protein) expressed by rods and other retinal cells has been identified to affect survival of cones.^{315,316} RdCVF does not directly cause cone death but may predispose cones to be more susceptible to oxidative and metabolic stress.^{317,318} As the rods degenerate, there is a decrease in oxygen consumption as there are fewer photoreceptors to utilize oxygen. Decreased oxygen consumption increases oxygen levels in the outer retina spreading to the inner retina (central retina).³¹⁹ This increase in oxygen levels leads to the increase in superoxide radical production. The antioxidants within the retina are overwhelmed

and may lead to increased oxidative stress.³²⁰ The oxidative stress on the cones increases and may cause cone death.³²¹ The increase in oxygen levels in the inner retina due to rod death may lead to narrowing of blood vessels via autoregulation of vasculature.

Signs and Symptoms

Patients with RP first complain of night blindness, then progress to loss of peripheral visual field, and late in the disease may lose central vision. This progression typically takes decades to progress to central vision loss, but a few variations of the disease progress earlier. Night blindness presents early in recessive RP, median age of 11, and dominant RP presents later in life, median age of 24.³¹³ Night blindness presents as disorientation in dim light or adaptation to dim light in a movie theater or tunnel is slower than normal. Earlier onset of night blindness is indicative of a faster progression of the disease. Daily vision such as reading, driving, or other tasks, are not affected in the early stages as only the rods are affected. As peripheral vision is lost, the visual field narrows causing patients to often bump into objects and other persons or notice objects seem to “just appear”. This stage of the disease is typically when patients are diagnosed as patients begin to notice symptoms. Constriction of visual field may progress 5-20% annually depending on gene affected and object used to test visual field.³²² Cystic spaces of fluid within the fovea, cystoid macular edema, may be observed during this stage of the disease. Pigment changes within the peripheral retina and narrowing of blood vessels are commonly observed on fundoscopic examination. Pigment is released as rods die. Visual acuity is normal until later stages of the disease as the cones are affected.^{313,323} Posterior subcapsular cataracts are commonly observed.³²⁴ Severe vision impairment occurs approximately around 40 to 50 years of age.

Diagnosis

Diagnosis of RP is made by history, fundus exam, and testing results (Goldmann perimetry and full-field electroretinogram). The average age at diagnosis for dominant RP and recessive is 36.9 and 36.2, respectively and median age of 40. At diagnosis, patients may present in the early stages with minimal or no vision loss or present with severe visual field deficits.³¹³ The age of onset is genetically determined and dependent on mode of inheritance. Fundoscopy exam of RP eyes typically demonstrates attenuation (narrowing) of blood vessels, waxy pallor of optic disc, and intraretinal pigmentation in a specific pattern, bone-spicule pattern.³²⁴ Full-field electroretinography (ERG) and multi-field ERG measure the electrical response of the retina to light and can record response to rods and cones separately. The amplitude correlates with size of visual field. Those with RP have a smaller amplitude and a slower response to the ERG stimulus. Multi-field ERG measures a specific portion of the retina.^{325,326,327} Spectral domain-optical coherence tomography (SD-OCT) can be used to visualize cone loss. Optical coherence tomography angiography (OCTA) is a newer technology to observe changes in vasculature associated with cone death.^{328,329} OCT is not a common diagnostic tool but may be used. Determination of the mode of inheritance is important to determine the risk to family members having RP and prognosis of the patient. Molecular diagnosis of RP can be accomplished by the following technologies: chain-terminating sequencing or Sanger method, Illumina sequencing system, Ion Turrent Semiconductor sequencing, DNA chip technology, single nucleotide

polymorphism (SNPs), High Resolution Melting (HRM) analysis, and Multiplex Ligation Probe Amplification (MLPA).³¹⁴

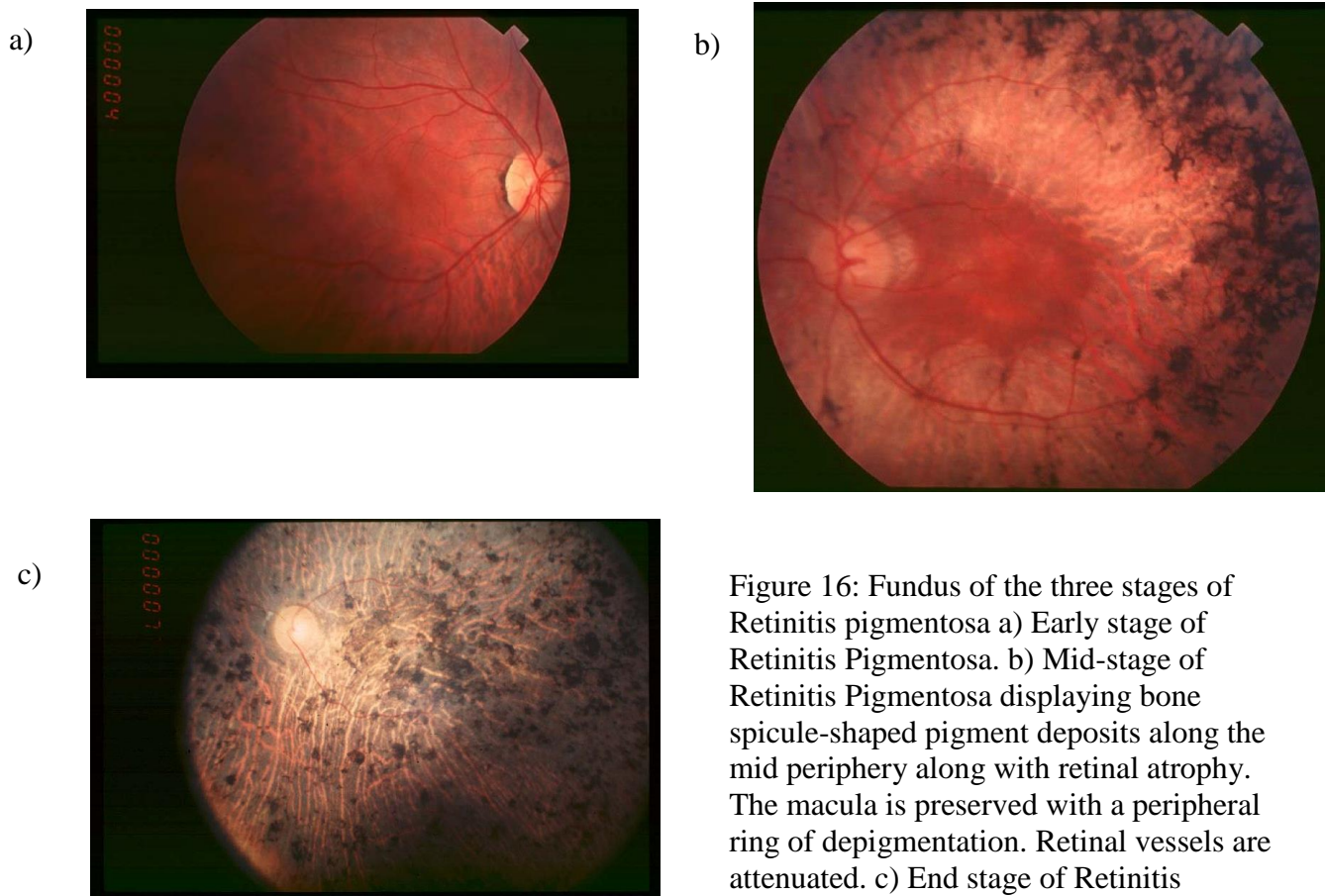


Figure 16: Fundus of the three stages of Retinitis pigmentosa a) Early stage of Retinitis Pigmentosa. b) Mid-stage of Retinitis Pigmentosa displaying bone spicule-shaped pigment deposits along the mid periphery along with retinal atrophy. The macula is preserved with a peripheral ring of depigmentation. Retinal vessels are attenuated. c) End stage of Retinitis Pigmentosa Pigment with deposits all over the retina and retinal vessels are extremely thin. The optic disc is very pale.³³⁰

Treatment

An effective treatment to prevent vision impairment for Retinitis Pigmentosa is not available. It is recommended in the early stages RP patients to avoid excessive light to limit stress on photoreceptors, such as, sunglasses.³³¹ Vitamin therapy, Vitamin A and Vitamin E, are recommended to slow down progression of RP. Vitamin A may be associated with slower loss of cone death in children with RP;³³² however, some studies have found no effect of Vitamin A and fish oil (DHA) on cone degeneration.³³³ Excessive amounts of Vitamin A is toxic and should be taken with caution, particularly pregnant and those with osteoporosis. Supplemental vitamin E is not recommended unless a patient has a rare form of RP that can be effectively treated with it.³³¹ Specific mutation identification is critical for childhood retinopathies for a quicker diagnosis and to distinguish RP from other possible retinal diseases.³⁰⁷ Alternative treatment may include acupuncture.³³⁴ Late stage RP vision impairment can be mitigated by the help of visual aids. As vision impairment progresses professional help should be sought to help adapt and learn skills

needed for low vision. RP patients tend to have difficulty adjusting to vocational, social, and health-care environment as vision loss progresses.³³¹

Future treatments are focused on the biochemical mechanism causing rod and cone death. These treatments are gene therapy, pharmacologic, retinal implants, and retinal transplants, focusing on preventing degeneration in the early stages. Gene augmentation, combined gene-slicing, and gene replacement are forms of gene therapy. Gene therapy is found to be effective for a rare form of RP, Leber congenital amaurosis (LCA).³³⁵ Pharmacologic treatment may be most effective when the pathophysiologic mechanism is known. Neuroprotection has potential to treat RP by providing neurotrophic factors, inhibitors of apoptosis, calpain inhibitors, and rod-derived viability factor.³³¹ Electrical retinal implants or artificial implants may be able to restore vision. Visual implants have a slow learning curve, but some improvement in vision and quality of life may be observed.³³⁶ Retinal cell transplantation shows promising results to improve vision in the future but is not a standard treatment.³³⁷ Animal models and clinical trials are necessary to continue to demonstrate effectiveness of these newer treatments.³³¹

Complications associated with RP such as posterior subcapsular cataracts, macular edema, and mild-inflammatory reactions can be treated. Posterior subcapsular cataracts can be treated via phacoemulsification. Macular edema can be treated with oral carbonic anhydrase inhibitors and mild inflammatory reactions typically self-resolve.³³¹

Retinal Detachment

Overview

Retinal detachment occurs when the retina separates from the retinal pigment epithelium and choroid layer beneath. This is a relatively common condition, occurring in 1 in 10,000 persons annually, and can cause significant vision loss without appropriate treatment.³³⁸ This is one of the most time-critical emergencies presented in an emergency setting regarding the eye. The retina is a complex organization of layers of neurons that capture light and convert light into neuronal signals that are sent to the visual cortex in the brain. Retinal detachment can occur due to a break in the retina, excessive fluid between the layers, or due to vitreous traction on the retina. The separation of the retina from the retinal pigment epithelium and choroid layer may lead to ischemia and fluid accumulation causing degeneration of the photoreceptors. Retinal detachment can be divided by pathophysiology into rhegmatogenous (caused by a hole or tear in the retina), nonrhegmatogenous (caused by leakage or exudation from beneath the retina), or vitreous traction pulling on the retina. Rhegmatogenous retinal detachments (RRD) are the most common. Fast and efficient diagnosis of a retinal detachment is critical to avoid permanent vision loss. This is best accomplished through recognition of common signs and symptoms.

Epidemiology

Incidence of approximately 1 in 10,000 persons annually. Those between the ages of 55 and 70 years of age are at the greatest risk of rhegmatogenous retinal detachment.³³⁸ Males are more likely to suffer from a retinal detachment.³³⁹ Those with a previous posterior vitreous detachment in one eye is at a considerable risk of development in the other eye within 6 months to 2 years and increases in prevalence with age in the fifth and ninth decade, specifically in the ninth decade.^{340,341}

Risk Factors

The risk factors for rhegmatogenous retinal detachment includes myopia,³⁴² cataract surgery, fluoroquinolones, lattice degeneration, posterior vitreous detachment, and trauma.^{338,343} Risk factors for PVD include female, myopia, trauma, or intraocular inflammation.³⁴⁴ Lattice degeneration is present in approximately 6-8% of both clinical and autopsy studies and is an atrophic disease affecting the peripheral retina in a lattice pattern. It may lead to tears or holes in the retina.³⁴⁵ A family history may play a role in the risk of a rhegmatogenous retinal detachment.³⁴³ An occupation involving heavy-lifting may put an individual at risk for a retinal detachment due to the increase in intraocular pressure during the Valsalva maneuver.³⁴⁶

Pathogenesis

Retinal detachment can be categorized into three types: rhegmatogenous, nonrhegmatogenous, and tractional. Each of these categories of retinal detachment can cause permanent vision loss due to apoptosis of photoreceptors cells. The degeneration of the photoreceptor cells may be due to TNF α as it plays a critical role in this process.³⁴⁷

Rhegmatogenous retinal detachment is due to a break (hole or tear) in the retina allowing fluid to accumulate between the retina and underlying structures. Holes and tears may be asymptomatic or symptomatic with asymptomatic less likely to lead to retinal detachment. RRD can be further split into posterior vitreous detachment (PVD) and traumatic retinal detachment. It is characterized as the separation of the posterior cortical vitreous from the internal membrane of the retina due to vitreous degeneration and shrinkage.³⁴⁴ PVD is most common in those 50 to 75 years of age as the vitreous fluid of the posterior chamber slowly liquifies throughout the eye's lifetime. If a tear or hole develops due to PVD or trauma, fluid may accumulate pulling the retina off of the underlying structures. Non-rhegmatogenous is caused by fluid accumulating between the photoreceptors and underlying structures without a break in the retina. This can be due to tumor growth or inflammation. Adhesions between the vitreous gel or fibrovascular proliferation and the retina can cause tractional retinal detachment by putting tension on the retina. This may result in a tear or hole and is typically caused by diabetic retinopathy, sickle cell disease, advanced retinopathy of prematurity, and trauma. Diabetic proliferative retinopathy that causes a tractional detachment may progress to resemble a rhegmatogenous component.³⁴⁸

Signs and Symptoms

The majority of patients presenting with retinal detachment report abnormal vision that may include an increase in number of floaters, photopsia (flashes of light), or difficulty determining which eye is affected. PVD is associated with increased number of floaters, flashes, and decreased vision.³⁴⁹ If the retina becomes detached, often a light to dark grey shadow is seen in the field of vision. Many patients notice the visual symptoms quickly, but often do not seek medical help due to lack of understanding of retinal detachment symptoms.³³⁸ A shower of floaters is commonly associated with a shower of floaters and accompanies vitreous hemorrhage. This may progress to a substantial decrease in vision. The loss of reading ability may occur with retinal detachments involving the macula.

Diagnosis

If a patient is experiencing changes in vision or increase in floaters or photopsia (flashes of light), they should seek care from their primary care physician or optometrist. A complete patient history should be obtained to determine if a trauma occurred. High-risk conditions are vitreous hemorrhage, visual field loss, or vitreous pigment should be referred quickly for further examination by an ophthalmologist or retinal surgeon. A slit-lamp biomicroscopy and dilated retinal exam should be completed on all patients. A complete ophthalmologic examination may be completed including: a best-corrected visual acuity (BCVA) using the Snellen chart, slit-lamp biomicroscopy, slit-lamp dilated fundus examination, and SD-OCT examination.³⁴⁴ An anterior segment examination may show particles, often referred to a “tobacco dust” (retinal pigment cells), and indicates a full-thickness retinal break. A funduscopy exam of the entire retina will demonstrate the detachment with the hole responsible commonly visible. The hole responsible for the detachment is more difficult to detect after cataract surgery.³³⁸ Ultrasounds may be modestly accurate in distinguishing retinal detachments from PVD.³⁵⁰

Treatment

Treatment of retinal detachments requires prompt action by the primary care physician or ophthalmologist. When the patient first presents with a retinal detachment, do not allow the patient to consume any food or liquids until cleared by a physician. In case of trauma, cover eye with an eye-shield. Avoidance of physical activity should be avoided. The fovea is the area of the retina with the best visual acuity and contrast sensitivity. The best visual outcomes occur without fovea involvement and relies on prompt recognition by the patient and primary physician of the retinal detachment.³⁵¹ After initial examination, a retinal surgeon or ophthalmologist should be sought for further treatment.

Posterior vitreous detachment typically only requires education and reassurance for the patient. A vitrectomy and pars plana vitrectomy are performed with positive outcomes for PVD. These procedures are not indicated for most patients unless symptoms are severe. Reevaluation is recommended to ensure further complications have not occurred.³⁵² Retinal hold or tear is best treated with laser retinopexy or cryoretinopexy due to low risk of complications. Laser photocoagulation can also be performed to correct a retinal hold or tear. RRD is commonly

treated via pneumatic retinopexy, temporary peribulbar balloon, scleral buckling, and/or pars plana vitrectomy, particularly for uncomplicated retinal detachment. Scleral buckling is best performed with good visual acuity, clear crystalline lens, and partial retinal detachment and has few complications.³⁵³ Traditional scleral buckling has a steep learning curve and uses indirect ophthalmoscope; however, chandelier-assisted scleral buckling surgery allows wide-angled viewing system during surgery and does not use an indirect ophthalmoscope (rather a slit-lamp). Both have similar reattachment rates.³⁵⁴ Tractional retinal detachment may be treated with pars plana vitrectomy in those with diabetic proliferative retinopathy. Systemic treatment of diabetes is a beneficial treatment option for the diabetic patient. Surgery is not always performed for peripheral detachments or chronic macular retinal detachment.³⁴⁸

CONCLUSION

This review demonstrates the complexity of the eye and the effect of chronic eye pathologies on vision and quality of life. Sadly, many of the pathologies included predominantly affect persons 75 years of age and older. Some pathologies that previously considered severe VI and blindness are considered preventable. Cataracts falls into this category as new IOL technology has revolutionized prognosis and dependence on corrective lenses. Many diseases still have unknown pathogenesis and require early detection for positive outcomes, such as, glaucoma, diabetic retinopathy, retinoblastoma, etc.

The web application and pathology literature review provide a resource of the most common and debilitating eye pathologies for pre-health students, allied health professionals, and interested individuals. It provides an overview, epidemiology, risk factors, pathophysiology, signs and symptoms, diagnosis, and treatment for the 11 pathologies included. A website has the capability for a user to search and scroll the various pathologies easily. Anatomy of the eye, including extraocular muscles, are provided on the home page. The understanding of the anatomy of the eye itself and the extraocular muscles may lead to a better understanding of the most common pathologies affecting the eye. The majority of eye pathologies that cause VI and blindness negatively influence the pathway of light through and to the cornea, lens, and retina.

The overall epidemiology of the various effects the older population, those 75 years of age and older, and those with systemic diseases, such as diabetes, hypertension, and immune-compromised individuals. With the aging of the United States population, there is predicted to be an increase in the overall prevalence of glaucoma, age-related macular degeneration, and diabetic retinopathy. Ethnicity does not seem to play a large role in the incidence and prevalence of the majority of eye pathologies. Risk factors regarding eye pathologies vary in each pathology. Common modifiable risk factors consist of smoking, UV light exposure, diet and exercise. Family history due to inheritance of predisposing genetic factors or mutations also is a common risk factor found in many of the pathologies.

The understanding of the pathophysiology plays an integral role in the effectiveness of treatment in each disease. Many of the eye diseases have an unknown mechanism and development of disease which prevents effective treatment and prediction of the development of specific diseases. For example, glaucoma is the degeneration of the optic disc due to increased IOP or

vascular disturbances. Due to the unknown mechanism of degeneration of the optic disc, once degeneration occurs it cannot be reversed. This requires early detection and hopefully prevention of progression to prevent substantial vision loss. Research regarding pathophysiology is necessary for effective treatment and overall better understanding of the disease processes.

Persons experiencing vision disturbances or in a high-risk population for specific ophthalmic pathologies should be proactive with their eye health and see an ophthalmologist or optometrist. Early detection is key in the prognosis of the various diseases. The review can be used as a resource for those affected by; those who treat medically; those interested in common causes vision impairment and blindness.

References

1. Varma R, Vajaranant TS, Burkemper B, et al. Visual Impairment and Blindness in Adults in the United States. *JAMA Ophthalmology*. 2016;134(7):802-809. doi:10.1001/jamaophthalmol.2016.1284. Accessed October 1, 2018.
2. Umfress AC, Brantley MA. Eye Care Disparities and Health-Related Consequences in Elderly Patients with Age-Related Eye Disease. *Seminars in Ophthalmology*. 2016;31(4):432-438. doi:10.3109/08820538.2016.1154171. Accessed October 1, 2018.
3. Wood JM, Black AA. Ocular disease and driving. *Clinical & Experimental Optometry*. 2016;99(5):395-401. doi:10.1111/cxo.12391. Accessed October 1, 2018.

4. Crews JE, Chou C-F, Zack MM, et al. The Association of Health-Related Quality of Life with Severity of Visual Impairment among People Aged 40–64 Years: Findings from the 2006–2010 Behavioral Risk Factor Surveillance System. *Ophthalmic Epidemiology*. 2016;23(3):145-153. doi:10.3109/09286586.2016.1168851. Accessed October 1, 2018.
5. Wittenborn JS, Zhang X, Feagan CW, Crouse WL, Shrestha S, Kemper AR, Hoerger TJ, Saaddine JB. The economic burden of vision loss and eye disorders among the United States population younger than 40 years. *Ophthalmology*. 2013;120(9):1728–1735. Accessed October 1, 2018.
6. Rein DB, Zhang P, Wirth KE, et al. The Economic Burden of Major Adult Visual Disorders in the United States. *Archives of Ophthalmology*. 2006;124(12):1754-1760. doi:10.1001/archophth.124.12.1754. Accessed October 1, 2018.
7. Chan T, Friedman DS, Bradley C, Massof R. Estimates of Incidence and Prevalence of Visual Impairment, Low Vision, and Blindness in the United States. *JAMA Ophthalmology*. 2018;136(1):12. doi:10.1001/jamaophthalmol.2017.4655. Accessed October 1, 2018.
8. Elam AR, Lee PP. High-Risk Populations for Vision Loss and Eye Care Underutilization: A Review of the Literature and Ideas on Moving Forward. *Survey of Ophthalmology*. 2013;58(4):348-358. doi:10.1016/j.survophthal.2012.07.005. Accessed October 1, 2018.
9. Purves D, Augustine GJ, Fitzpatrick D, et al. *Neuroscience*. 6th ed. New York, NY: Oxford University Press; 2018. Accessed October 1, 2018.
10. Congdon N, O'Colmain B, Klaver CC, et al. Causes and prevalence of visual impairment among adults in the United States. *Arch Ophthalmol*. 2004;122:477–85. Accessed September 15, 2018.
11. Haargaard B, Wohlfahrt J, Rosenberg T, Fledelius HC, Melbye M. Risk factors for idiopathic congenital/infantile cataract. *Investigative Ophthalmology & Visual Science*. 2005;46(9):3067-3073.
<http://pointloma.idm.oclc.org/login?url=http://search.ebscohost.com/login.aspx?direct=true&db=mnh&AN=16123403&site=ehost-live>. Accessed February 12, 2019.
12. Rasul A, Kessel L. Prevalence of anterior polar cataracts in children and risk factors for amblyopia. *Acta Ophthalmologica*. November 2018. doi:10.1111/aos.13966.
13. Mundy KM, Nichols E, Lindsey J. Socioeconomic Disparities in Cataract Prevalence, Characteristics, and Management. *Seminars in Ophthalmology*. 2016;31(4):358-363. doi:10.3109/08820538.2016.1154178. Accessed September 15, 2018.
14. Ahuja R. Slit lamp view of human cataract.
https://commons.wikimedia.org/wiki/File:Slit_lamp_view_of_Cataract_in_Human_Eye.png. Published July 20, 2006
15. Cataracts. *National Eye Institute*. <https://nei.nih.gov/eyedata/cataract>. Accessed August 15, 2018. Accessed September 15, 2018.
16. Sanders JL, Lannaccone A, Boudreau RM, et al. The association of cataract with leukocyte telomere length in older adults: Defining a new marker of aging. *The Journals of Gerontology: Series A: Biological Sciences and Medical Sciences*. 2011;66(6):639-645. doi:10.1093/gerona/66(6). Accessed September 15, 2018.
17. Nam SW, Lim DH, Cho KY, Kim HS, Kim K, Chung T-Y. Risk factors of presenile nuclear cataract in health screening study. *BMC Ophthalmology*. 2018;18(1):263. doi:10.1186/s12886-018-0928-6. Accessed September 16, 2018.

18. Ye J, He J, Wang C, Wu H, Shi X, Zhang H, Xie J, Lee SY. Smoking and risk of age-related cataract: a meta-analysis. *Invest Ophthalmol Vis Sci*. 2012;53(7):3885–95. Accessed September 16, 2018.
19. Yonova-Doing E, Forkin ZA, Hysi PG, et al. Genetic and Dietary Factors Influencing the Progression of Nuclear Cataract. *Ophthalmology*. 2016;123(6):1237-1244. doi:10.1016/j.ophtha.2016.01.036 Accessed September 16, 2018.
20. Sweeney J, Patterson CC, Menzies-Gow A, Niven RM, Mansur AH, Bucknall C, Chaudhuri R, Price D, Brightling CE, Heaney LG. Comorbidity in severe asthma requiring systemic corticosteroid therapy: cross-sectional data from the optimum patient care research database and the British thoracic difficult asthma registry. *Thorax*. 2016;71(4):339–46. Accessed September 16, 2018.
21. Drinkwater JJ, Davis WA, Davis TME. A systematic review of risk factors for cataract in type 2 diabetes. *Diabetes/Metabolism Research And Reviews*. 2019;35(1):e3073. doi:10.1002/dmrr.3073. Accessed September 16, 2018.
22. Tarwadi KV, Chiplonkar SA, Agte V. Dietary and nutritional biomarkers of lens degeneration, oxidative stress and micronutrient inadequacies in Indian cataract patients. *Clin Nutr*. 2008;27(3):464 –72. 44.
23. Kurtoglu E, Ugur A, Baltaci AK, Undar L. Effect of iron supplementation on oxidative stress and antioxidant status in iron-deficiency anemia. *Biol Trace Elem Res*. 2003;96(1 – 3):117 –23.
24. Johnson AC, Lee JW, Harmon AC, et al. A mutation in the start codon of γ -crystallin D leads to nuclear cataracts in the Dahl SS/Jr-Ctr strain. *Mammalian Genome: Official Journal Of The International Mammalian Genome Society*. 2013;24(3-4):95-104. doi:10.1007/s00335-013-9447. Accessed September 16, 2018.
25. Causes of Cataracts. Vision. January 2010:5-8. <http://pointloma.idm.oclc.org/login?url=http://search.ebscohost.com/login.aspx?direct=true&db=hxh&AN=67520989&site=ehost-live>. Accessed January 4, 2019.
26. Leo T, Chylack Jr, Wolfe JK, Singer DM, et al. The Lens Opacities Classification System III. *Arch Ophthalmol*. 1993;111(6):831-836. doi:10.1001/archopht.1993.01090060119035
27. Fan X, Liu X, Hao S, Wang B, Robinson ML, Monnier VM. The LEGSKO mouse: a mouse model of age-related nuclear cataract based on genetic suppression of lens glutathione synthesis. *PLoS One*. 2012;7(11):e50832. doi:10.1371/journal.pone.0050832.
28. Lynnerup N, Kjeldsen H, Heegaard S, Jacobsen C, Heinemeier J. Radiocarbon Dating of the Human Eye Lens Crystallines Reveal Proteins without Carbon Turnover throughout Life. *PLoS ONE*. 2008;3(1). doi:10.1371/journal.pone.0001529
29. Hains PG, Truscott RJW. Proteomic analysis of the oxidation of cysteine residues in human age-related nuclear cataract lenses. *Biochimica Et Biophysica Acta*. 2008;1784(12):1959-1964. doi:10.1016/j.bbapap.2008.07.016.
30. Datiles MB 3rd, Ansari RR, Yoshida J, et al. Longitudinal Study of Age-Related Cataract Using Dynamic Light Scattering: Loss of α -Crystallin Leads to Nuclear Cataract Development. *Ophthalmology*. 2016;123(2):248-254. doi:10.1016/j.ophtha.2015.10.007.
31. Feldman BH, Heersink S. Cataract. EyeWiki. <http://eyewiki.aao.org/Cataract#Symptoms>. Published June 17, 2018. Accessed February 12, 2019.

32. Babizhayev MA, Minasyan H, Richer SP. Cataract halos: A driving hazard in aging populations. Implication of the Halometer DG test for assessment of intraocular light scatter. *Applied Ergonomics*. 2009;40(3):545-553. doi:10.1016/j.apergo.2007.09.003.
33. Khazaeni LM. Cataract - Eye Disorders. Merck Manuals Professional Edition. <https://www.merckmanuals.com/professional/eye-disorders/cataract/cataract>. Published November 2017. Accessed February 12, 2019.
34. Riaz Y. Surgical interventions for age-related cataract. Mehta JS, Wormald R, Evans JR, Foster A, Ravilla T, Snellings T, eds. *Cochrane Database of Systematic Reviews*. 2008;(1). <http://pointloma.idm.oclc.org/login?url=http://search.ebscohost.com/login.aspx?direct=true&db=chh&AN=CD001323&site=ehost-live>. Accessed January 4, 2019.
35. Ong HS. Accommodative intraocular lens versus standard monofocal intraocular lens implantation in cataract surgery. Evans JR, Allan BD, eds. *Cochrane Database of Systematic Reviews*. 2014;(5). <http://pointloma.idm.oclc.org/login?url=http://search.ebscohost.com/login.aspx?direct=true&db=chh&AN=CD009667&site=ehost-live>. Accessed February 12, 2019.
36. De Silva SR. Multifocal versus monofocal intraocular lenses after cataract extraction. Evans JR, Kirithi V, Ziaei M, Leyland M, eds. *Cochrane Database of Systematic Reviews*. 2016;(12). <http://pointloma.idm.oclc.org/login?url=http://search.ebscohost.com/login.aspx?direct=true&db=chh&AN=CD003169&site=ehost-live>. Accessed February 12, 2019.
37. Facts about Cataracts. *National eye institute*. https://nei.nih.gov/health/cataract/cataract_facts. Reviewed September 2015. Accessed February 12, 2019.
38. Ahmed IK. Microinvasive Glaucoma Surgery and Cataract Surgery Synergy. *Focal Points*. 2018;36(1):1-14. Accessed March 13, 2019.
39. Pillunat L, Erb C, Jünemann AG, Kimmich F. Micro-invasive glaucoma surgery (MIGS): a review of surgical procedures using stents. *Clin Ophthalmol*. 2017; 11: 1583–1600. doi:10.2147/OPHTH.S135316. Accessed March 13, 2019.
40. Van Cleynenbreugel H, Remeijer L, Hillenaar T. Cataract surgery in patients with Fuchs' endothelial corneal dystrophy: when to consider a triple procedure. *Ophthalmology*. 2014;121(2):445-453. doi:10.1016/j.ophtha.2013.09.047. Accessed March 3, 2019.
41. Ao M, Li X, Huang C, Hou Z, Qiu W, Wang W. Significant Improvement in Dynamic Visual Acuity after Cataract Surgery: A Promising Potential Parameter for Functional Vision. *PLoS ONE*. 2014;9(12):1-11. doi:10.1371/journal.pone.0115812.
42. Groessl E, Liu L, Sklar M, Tally S, Kaplan R, Ganiats T. Measuring the impact of cataract surgery on generic and vision-specific quality of life. *Quality of Life Research*. 2013;22(6):1405-1414. doi:10.1007/s11136-012-0270-z.
43. Zhu B, Ma Y, Lin S, Zou H. Vision-related quality of life and visual outcomes from cataract surgery in patients with vision-threatening diabetic retinopathy: a prospective observational study. *Health And Quality Of Life Outcomes*. 2017;15(1):175. doi:10.1186/s12955-017-0751-4
44. Weinreb RN, Khaw PT. Primary open-angle glaucoma. *Lancet*. 2004;363(9422):1711-20. doi:10.1016/S0140-6736(04)16257-0

45. Congdon NG, Friedman DS. Angle-closure glaucoma: impact, etiology, diagnosis, and treatment. *Curr Opin Ophthalmol*. 2003;14(2):70-3. <https://insights.ovid.com/pubmed?pmid=12698044>. Accessed February 10, 2019.
46. Mantelli F, Bruscolini A, La Cava M, Abdolrahimzadeh S, Lambiase A. Ocular manifestations of Sturge-Weber syndrome: pathogenesis, diagnosis, and management. *Clinical Ophthalmology* (Auckland, NZ). 2016;10:871-878. doi:10.2147/OPHTH.S101963. Accessed February 10, 2019.
47. Taylor RH, Ainsworth JR, Evans AR, Levin AV. The epidemiology of pediatric glaucoma: the Toronto experience. *J AAPOS*. 1999;3(5):308-15. doi:10.1016/S1091-8531(99)70028-5. Accessed February 12, 2019.
48. Kang JH, Juan Wu, Eunyoung Cho, et al. Contribution of the Nurses' Health Study to the Epidemiology of Cataract, Age-Related Macular Degeneration, and Glaucoma. *American Journal of Public Health*. 2016;106(9):1684-1689. doi:10.2105/AJPH.2016.303317. Accessed December 16, 2018.
49. Tham, Y., Li, X., Wong, T. Y., Quigley, H. A., Aung, T., & Cheng, C. (2014). Re: Tham et al.: Global prevalence of glaucoma and projections of glaucoma burden through 2040: A systematic review and meta-analysis (*Ophthalmology* 2014;121:2081-90). Accessed December 16, 2018.
50. Quigley HA, Broman AT. The number of people with glaucoma worldwide in 2010 and 2020. *The British Journal Of Ophthalmology*. 2006;90(3):262-267. doi:10.1136/bjo.2005.081224. Accessed February 14, 2019.
51. Glaucoma, open-angle. *National Eye Institute*. <https://nei.nih.gov/eyedata/glaucoma>. Accessed February 15, 2019.
52. Kinouchi R, Ishiko S, Hanada K, et al. A low meat diet increases the risk of open-angle glaucoma in women—The results of population-based, cross-sectional study in Japan. *PLoS ONE*. 2018;13(10):1-12. doi:10.1371/journal.pone.0204955. Accessed December 16, 2018.
53. Czudowska MA, Ramdas WD, Wolfs RC, Hofman A, De Jong PT, Vingerling JR, Jansonius NM. Incidence of glaucomatous visual field loss: a ten-year follow-up from Rotterdam Study. *Ophthalmology*. 2010;117(9):1705. doi:10.1016/j.ophtha.2010.01.034. Accessed February 12, 2019.
54. Varma R, Wang D, Wu C, Francis BA, Nguyen BB, Chopra V, Memarzadeh F, Torres M, Azen SP. Four-year incidence of open-angle glaucoma and ocular hypertension: the Los Angeles Latino Eye Study: the Los Angeles Latino Eye Study. *Am J Ophthalmol*. 2012;154(2)L315. doi:10.1016/j.ajo.2012.02.014. Accessed February 12, 2019.
55. Sommer A, Tielsch JM, Katz J, Quigley HA, Gottsch JD, Javitt JC, Martone JF, Royall RM, Witt KA, Ezrine S. Racial differences in the cause-specific prevalence of blindness in east Baltimore. *N Engl J Med*. 1991;325(20):1412. doi:10.1056/NEJM199111143252004. Accessed December 16, 2018.
56. Haymes SA, Leblanc RP, Nicolela MT, Chiasson LA, Chauhan BC. Risk of falls and motor vehicle collisions in glaucoma. *Invest Ophthalmol Vis Sci*. 2007;48(3):1149. doi:10.1167/iovs.06-0886. Accessed February 10, 2019.
57. Richman J, Lorenzana LL, Lankaranian D, Dugar J, Mayer JR, Wizov SS, Spaeth GL. Relationships in glaucoma patients between standard vision tests, quality of life, and ability to perform daily activities. *Ophthalmic Epidemiol*. 2010;17(3):144-51. doi:10.3109/09286581003734878. Accessed February 10, 2019.

58. Ang GS, Eke T. Lifetime visual prognosis for patients with primary open-angle glaucoma. *Eye (Lond)*. 2007;21(5):604-8. doi:10.1038/sj.eye.6702284. Accessed February 10, 2019.
59. Coleman AL, Miglior S. Risk factors for glaucoma onset and progression. *Surv Ophthalmol*. 2008;53(6):S3-S10. doi:10.1016/j.survophthal.2008.08.006. Accessed February 12, 2019.
60. Alzuhairy S, Abu-Amero KK, Al-Shahwan S, Edward DP. A Novel CYP1B1 Mutation with Congenital Glaucoma and Total Aniridia. *Ophthalmic Genetics*. 2015;36(1):89-91. doi:10.3109/13816810.2013.833635. Accessed July 16, 2018.
61. Kwon YH, Fingert JH, Kuehn MH, Alward WL. Primary open-angle glaucoma. *N Engl J Med*. 2009;360(11):1113. doi:10.1056/NEJMra0804630. Accessed December 17, 2018.
62. Pasquale LR, Kang JH. Female reproductive factors and primary open-angle glaucoma in the Nurses' Health Study. *Eye (London, England)*. 2011;25(5):633-641. doi:10.1038/eye.2011.34.
63. Wang YE, Kakigi C, Barbosa D, et al. Oral Contraceptive Use and Prevalence of Self-Reported Glaucoma or Ocular Hypertension in the United States. *Ophthalmology*. 2016;123(4):729-736. doi:10.1016/j.ophtha.2015.11.029. Accessed December 16, 2018.
64. Hung C-H, Lee S-H, Lin S-Y, Lin S-L, Chen Y-C. The relationship between optic nerve head deformation and visual field defects in myopic eyes with primary open-angle glaucoma. *PLoS ONE*. 2018;13(12):1-14. doi:10.1371/journal.pone.0209755. Accessed January 18, 2019.
65. Bengtsson B, Leske MC, Hyman L, Heijl A. Fluctuation of intraocular pressure and glaucoma progression in the early manifest glaucoma trial. *Ophthalmology*. 2007;114(2):205. doi:10.1016/j.ophtha.2006.07.060. Accessed February 12, 2019.
66. Zhao D, Cho J, Kim MH, Friedman DS, Guallar E. Diabetes, fasting glucose, and the risk of glaucoma: a meta-analysis. *Ophthalmology*. 2015 Jan;122(1):72-8. doi:10.1016/j.ophtha.2014.07.051. January 18, 2019.
67. Zhao D, Cho J, Kim MH, Guallar E. The association of blood pressure and primary open-angle glaucoma: a meta-analysis. *Am J Ophthalmol*. 2014 Sep;158(3):615-27.e9. doi:10.1016/j.ajo.2014.05.029. Accessed February 12, 2019.
68. Santaella RM, Fraunfelder FW. Ocular Adverse Effects Associated with Systemic Medications: Recognition and Management. *Drugs*. 2007;67(1):75-93. <http://pointloma.idm.oclc.org/login?url=http://search.ebscohost.com/login.aspx?direct=true&db=s3h&AN=23684643&site=ehost-live>. Accessed February 14, 2019.
69. Richa S, Yazbek J-C. Ocular adverse effects of common psychotropic agents: A review. *CNS Drugs*. 2010;24(6):501-526. doi:10.2165/11533180-000000000-00000. Accessed February 12, 2019.
70. Congdon N, Wang F, Tielsch JM. Issues in the epidemiology and population-based screening of primary angle-closure glaucoma. *Surv Ophthalmol*. 1992;36(6):411-423. <https://www.sciencedirect.com/science/article/pii/S0039625705800220?via%3Dihub>. Accessed February 13, 2019.
71. Rudzinski MN, Chen L, Hernandez MR. Antiangiogenic characteristics of astrocytes from optic nerve heads with primary open-angle glaucoma. *Archives Of Ophthalmology (Chicago, Ill: 1960)*. 2008;126(5):679-685. doi:10.1001/archophth.126.5.679. Accessed July 16, 2018.

72. Cheung LTY, Manthey AL, Lai JSM, Chiu K. Targeted Delivery of Mitochondrial Calcium Channel Regulators: The Future of Glaucoma Treatment? *Frontiers In Neuroscience*. 2017;11:648. doi:10.3389/fnins.2017.00648. Accessed February 14, 2019.
73. Harper R, Reeves B. The sensitivity and specificity of direct ophthalmoscopic optic disc assessment in screening for glaucoma: a multivariate analysis. *Graefes Arch Clin Exp Ophthalmol*. 2000;238(12):949. <https://www.ncbi.nlm.nih.gov/pubmed/?term=11196356>. Accessed September 20, 2018.
74. Santana, L. D., Inman, D. M., Lupien, C. B., Horner, P. J., & Wong, R. O. Differential Progression of Structural and Functional Alterations in Distinct Retinal Ganglion Cell Types in a Mouse Model of Glaucoma. *Journal of Neuroscience*. 2013;33(44), 17444-17457. doi:10.1523/jneurosci.5461-12.2013. Accessed September 18, 2018.
75. Nakanishi M, Wang YT, Jung TP, Zao JK, Chien YY, Diniz-Filho A, Daga FB, Lin YP, Wang Y, Medeiros FA. Detecting Glaucoma With a Portable Brain-Computer Interface for Objective Assessment of Visual Function Loss. *JAMA Ophthalmol*. 2017;125(6):550. doi:10.1001/jamaophthalmol.2017.0738. Accessed February 12, 2019.
76. Baek SU, Kim KE, Kim YK, Park KH, Jeoung JW. Development of Topographic Scoring System for Identifying Glaucoma in Myopic Eyes: A Spectral-Domain OCT Study. *Ophthalmology*. 2018;125(11):1710. doi:10.1016/j.optha.2018.05.002. Accessed February 12, 2019.
77. Pleet A, Sulewski M, Salowe RJ, et al. Risk Factors Associated with Progression to Blindness from Primary Open-Angle Glaucoma in an African-American Population. *Ophthalmic Epidemiology*. 2016;23(4):248-256. doi:10.1080/09286586.2016.1193207. Accessed February 14, 2019.
78. Sharif NA. Glaucomatous optic neuropathy treatment options: the promise of novel therapeutics, techniques and tools to help preserve vision. *Neural Regeneration Research*. 2018;13(7):1145-1150. doi:10.4103/1673-5374.235017. Accessed February 15, 2019.
79. Eichenbaum JW. Geriatric vision loss due to cataracts, macular degeneration, and glaucoma. *The Mount Sinai Journal Of Medicine, New York*. 2012;79(2):276-294. doi:10.1002/msj.21303. Accessed August 18, 2018.
80. Luibl V, Isas JM, Kayed R, Glabe CG, Langen R, Chen J. Drusen deposits associated with aging and age-related macular degeneration contain nonfibrillar amyloid oligomers. *The Journal Of Clinical Investigation*. 2006;116(2):378-385. <http://pointloma.idm.oclc.org/login?url=http://search.ebscohost.com/login.aspx?direct=true&db=mnh&AN=16453022&site=ehost-live>. Accessed February 19, 2019.
81. Congdon N, O'Colmain B, Klaver CC, et al. Causes and prevalence of visual impairment among adults in the United States. *Arch Ophthalmol*. 2004;122:477-85. doi:10.1001/archopht.122.4.477. Accessed February 17, 2019
82. Friedman DS1, O'Colmain BJ, Muñoz B, Tomany SC, McCarty C, de Jong PT, Nemesure B, Mitchell P, Kempen J. Prevalence of age-related macular degeneration in the United States. *Arch Ophthalmol*. 2004 Apr;122(4):564-72. doi:10.1001/archopht.122.4.564. February 16, 2019.
83. Klein R, Klein BE, Jensen SC, Meuer SM. The Five-year Incidence and Progression of Age-related Maculopathy. *Ophthalmology*. 1997;104(1):7-21. doi:10.1016/s0161-6420(97)30368-6. February 16, 2019.
84. Klein R1, Klein BE, Knudtson MD, Wong TY, Cotch MF, Liu K, Burke G, Saad MF, Jacobs DR Jr. Prevalence of age-related macular degeneration in 4 racial/ethnic groups in

- the multi-ethnic study of atherosclerosis. *Ophthalmology*. 2006 Mar;113(3):373-80. doi:10.1016/j.ophtha.2005.12.013. Accessed August 18, 2018.
85. Kawasaki R, Yasuda M, Song SJ, Chen SJ, Jonas JB, Wang JJ, Mitchell P, Wong TY. The prevalence of age-related macular degeneration in Asians: a systematic review and meta-analysis. *Ophthalmology*. 2010 May;117(5):921-7. Epub 2010 Jan 27. doi:10.1016/j.ophtha.2009.10.007. February 16, 2019.
86. Muñoz B1, Klein R, Rodriguez J, Snyder R, West SK. Prevalence of age-related macular degeneration in a population-based sample of Hispanic people in Arizona: Proyecto VER. *Arch Ophthalmol*. 2005 Nov;123(11):1575-80. doi: 10.1001/archophth.123.11.1575. Accessed February 16, 2019.
87. Friedman DS1, Katz J, Bressler NM, Rahmani B, Tielsch JM. Racial differences in the prevalence of age-related macular degeneration: the Baltimore Eye Survey. *Ophthalmology*. 1999 Jun;106(6):1049-55. doi:10.1016/S0161-6420(99)90267-1. February 16, 2019.
88. Rein DB1, Wittenborn JS, Zhang X, Honeycutt AA, Lesesne SB, Saaddine J; Vision Health Cost-Effectiveness Study Group. Forecasting age-related macular degeneration through the year 2050: the potential impact of new treatments. *Arch Ophthalmol*. 2009 Apr;127(4):533-40. doi:10.1001/archophthalmol.2009.58. February 16, 2019.
89. Meletis CD, Wilkes K. Common Ocular Conditions in Clinical Practice: Macular Degeneration, Glaucoma, Cataracts and Beyond. *Townsend Letter*. 2018;(417):64-69. <http://pointloma.idm.oclc.org/login?url=http://search.ebscohost.com/login.aspx?direct=true&db=awh&AN=128828104&site=ehost-live>. Accessed February 17, 2019.
90. Klein R1, Klein BE, Moss SE. Relation of smoking to the incidence of age-related maculopathy. The Beaver Dam Eye Study. *Am J Epidemiol*. 1998;147(2):103-10. <https://www.ncbi.nlm.nih.gov/pubmed/9456998>. Accessed August 18, 2018.
91. Klein R, Klein BE, Tomany SC, Moss SE. Ten-Year Incidence of Age-related Maculopathy and Smoking and Drinking: The Beaver Dam Eye Study. *American Journal of Epidemiology*. 2002;156(7):589-98. <https://doi.org/10.1093/aje/kwf092>. Accessed February 16, 2019.
92. Cruickshanks KJ1, Klein R, Klein BE. Sunlight and age-related macular degeneration. The Beaver Dam Eye Study. *Arch Ophthalmol*. 1993 Apr;111(4):514-8. <https://jamanetwork.com/journals/jamaophthalmology/fullarticle/vol/111/pg/514>. Accessed February 16, 2019.
93. Vila N, Siblino A, Esposito E, Bravo-Filho V, Zoroquiain P, Aldrees S, Logan P, Arias L, Burnier MN. Blue-light filtering alters angiogenic signaling in human retinal pigmented epithelial cells culture model. *BMC Ophthalmol*. 2017;17(1):198. doi:10.1186/s12886-017-0592-2. Accessed February 16, 2019.
94. Shahid H, Khan JC, Cipriani V, et al. Age-related macular degeneration: the importance of family history as a risk factor. *The British Journal Of Ophthalmology*. 2012;96(3):427-431. doi:10.1136/bjophthalmol-2011-300193. Accessed February 16, 2019.
95. Saksens NTM, Lechanteur YTE, Verbakel SK, et al. Analysis of Risk Alleles and Complement Activation Levels in Familial and Non-Familial Age-Related Macular Degeneration. *PLoS ONE*. 2016;11(6):1-12. doi:10.1371/journal.pone.0144367. Accessed February 16, 2019.
96. Klein RJ, Zeiss C, Chew EY, Tsai JY, Sackler RS, Haynes C, Henning AK, SanGiovanni JP, Mane SM, Mayne ST, Bracken MB, Ferris FL, Ott J, Barnstable C, Hoh J.

- Complement factor H polymorphism in age-related macular degeneration. *Science*. 2005;308(5720):385-9. doi:10.1126/science.1109557. Accessed February 16, 2019.
97. Ciulla TA, Harris A, Kagemann L, Danis RP, Pratt LM, Chung HS, Weinberger D, Garzosi HJ. Choroidal perfusion perturbations in non-neovascular age related macular degeneration. *Br J Ophthalmol*. 2002;86(2):209. <https://www.ncbi.nlm.nih.gov/pmc/articles/PMC1770996/>. Accessed February 16, 2019.
98. Friedman E. A hemodynamic model of the pathogenesis of age-related macular degeneration. *Am J Ophthalmol*. 1997 Nov;124(5):677-82. Accessed September 20, 2018.
99. Uranga RM, Bruce-Keller AJ, Morrison CD, Fernandez-Kim SO, Ebenezer PJ, Zhang L, Dasuri K, Keller JN. Intersection between metabolic dysfunction, high fat diet consumption, and brain aging. *J Neurochem*. 2010 Jul; 114(2):344-61. doi:10.1111/j.1471-4159.2010.06803.x. Accessed September 20, 2018.
100. Canter JA, Olson LM, Spencer K, Schnetz-Boutaud N, Anderson B, Hauser MA, Schmidt S, Postel EA, Agarwal A, Pericak-Vance MA, Sternberg P Jr, Haines JL. Mitochondrial DNA polymorphism A4917G is independently associated with age-related macular degeneration. *PLoS One*. 2008 May 7; 3(5):e2091. doi:10.1371/journal.pone.0002091. Accessed September 20, 2018.
101. SanGiovanni JP, Arking DE, Iyengar SK, Elashoff M, Clemons TE, Reed GF, Henning AK, Sivakumaran TA, Xu X, DeWan A, Agrón E, Rochtchina E, Sue CM, Wang JJ, Mitchell P, Hoh J, Francis PJ, Klein ML, Chew EY, Chakravarti A. Mitochondrial DNA variants of respiratory complex I that uniquely characterize haplogroup T2 are associated with increased risk of age-related macular degeneration. *PLoS One*. 2009; 4(5):e5508. doi: 10.1371/journal.pone.0005508. Accessed September 20, 2018.
102. Ferrington DA, Sinha D, Kaarniranta K. Defects in retinal pigment epithelial cell proteolysis and the pathology associated with age-related macular degeneration. *Progress in Retinal & Eye Research*. 2016;51:69-89. doi:10.1016/j.preteyeres.2015.09.002. Accessed September 20, 2018.
103. Assel MJ, Li F, Wang Y, Allen AS, Baggerly KA, Vickers AJ. Genetic Polymorphisms of CFH and ARMS2 Do Not Predict Response to Antioxidants and Zinc in Patients with Age-Related Macular Degeneration: Independent Statistical Evaluations of Data from the Age-Related Eye Disease Study. *Ophthalmology*. 2018;125(3):391-397. doi:10.1016/j.ophtha.2017.09.008. Accessed September 20, 2018.
104. Boyer DS, Schmidt-Erfurth U, Campagne MVL, Henry EC, Brittain C. The Pathophysiology Of Geographic Atrophy Secondary To Age-Related Macular Degeneration And The Complement Pathway As A Therapeutic Target. *Retina*. 2017;37(5):819-835. doi:10.1097/iae.0000000000001392. Accessed September 20, 2018.
105. Klein R, Myers CE, Meuer SM, et al. Risk Alleles in CFH and ARMS2 and the Long-term Natural History of Age-Related Macular Degeneration. *JAMA Ophthalmology*. 2013;131(3):383-392. doi:10.1001/jamaophthalmol.2013.713. Accessed September 20, 2018.
106. Tuo J, Grob S, Zhang K, Chan C-C. Genetics of immunological and inflammatory components in age-related macular degeneration. *Ocular Immunology And Inflammation*. 2012;20(1):27-36. doi:10.3109/09273948.2011.628432. Accessed September 20, 2018.
107. Wysong A, Lee PP, Sloan FA. Longitudinal incidence of adverse outcomes of age-related macular degeneration. *Archives Of Ophthalmology (Chicago, Ill: 1960)*.

- 2009;127(3):320-327. doi:10.1001/archophthalmol.2008.613. Accessed February 16, 2019.
108. Lane J, Rohan EMF, Sabeti F, et al. Impacts of impaired face perception on social interactions and quality of life in age-related macular degeneration: A qualitative study and new community resources. *PLoS ONE*. 2018;13(12):1-31. doi:10.1371/journal.pone.0209218. Accessed September 18, 2018.
109. A fundus photo showing intermediate age-related macular degeneration.; 2010. https://commons.wikimedia.org/wiki/File:Intermediate_age_related_macular_degeneration.jpg. Accessed March 16, 2019.
110. Holz FG1, Jorzik J, Schutt F, Flach U, Unnebrink K. Agreement among ophthalmologists in evaluating fluorescein angiograms in patients with neovascular age-related macular degeneration for photodynamic therapy eligibility (FLAP-study). *Ophthalmology*. 2003 Feb;110(2):400-5. doi: 10.1016/S0161-6420(02)01770-0. Accessed February 16, 2019.
111. Arslan S, Kadayifçilar S, Samur G. The Potential Role of Dietary Antioxidant Capacity in Preventing Age-Related Macular Degeneration. *Journal Of The American College Of Nutrition*. 2018:1-9. doi:10.1080/07315724.2018.1538830. Accessed February 16, 2019.
112. Age-Related Eye Disease Study Research Group. A randomized, placebo-controlled, clinical trial of high-dose supplementation with vitamins C and E, beta carotene, and zinc for age-related macular degeneration and vision loss: AREDS report no. 8. *Arch Ophthalmol*. 2001;119(10):1417. <https://www.ncbi.nlm.nih.gov/pmc/articles/PMC1462955/>. Accessed February 19, 2019.
113. Complications of Age-Related Macular Degeneration Prevention Trial Research Group. Laser treatment in patients with bilateral large drusen: the complications of age-related macular degeneration prevention trial. *Ophthalmology*. 2006;113(11):1974. doi:10.1016/j.ophtha.2006.08.015. Accessed February 19, 2019.
114. Vavvas DG, Daniels AB, Kapsala ZG, Goldfarb JW, Ganotakis E, Loewenstein JI, Young LH, Gragoudas ES, Elliott D, Kim IK, Tsilimbaris MK, Miller JW. Regression of Some High-risk Features of Age-related Macular Degeneration (AMD) in Patients Receiving Intensive Statin Treatment. *EBioMedicine*. 2016;5:198. Epub 2016 Feb 4. doi:10.1016/j.ebiom.2016.01.033. Accessed February 19, 2019.
115. Schwartz SD, Regillo CD, Lam BL, Elliott D, Rosenfeld PJ, Gregori NZ, Hubschman JP, Davis JL, Heilwell G, Spirn M, Maguire J, Gay R, Bateman J, Ostrick RM, Morris D, Vincent M, Anglade E, Del Priore LV, Lanza R. Human embryonic stem cell-derived retinal pigment epithelium in patients with age-related macular degeneration and Stargardt's macular dystrophy: follow-up of two open-label phase 1/2 studies. *Lancet*. 2015 Feb;385(9967):509-16. Epub 2014 Oct 15. doi:10.1016/S0140-6736(14)61376-3. Accessed February 16, 2019.
116. Martin, M. G. Maguire et al., "Ranibizumab and bevacizumab for neovascular age-related macular degeneration," *The New England Journal of Medicine*, vol. 364, no. 20, pp. 1897–1908, 2011. Accessed September 28, 2018.
117. Moja L. Systemic safety of bevacizumab versus ranibizumab for neovascular age-related macular degeneration. Lucenteforte E, Kwag KH, Bertele V, et al., eds. *Cochrane Database of Systematic Reviews*. 2014;(9). <http://pointloma.idm.oclc.org/login?url=http://search.ebscohost.com/login.aspx?direct=true&db=chh&AN=CD011230&site=ehost-live>. Accessed January 18, 2019.

118. Potter MJ, Szabo SM. Recurrence of choroidal neovascularisation after photodynamic therapy in patients with age-related macular degeneration. *Br J Ophthalmol*. 2007;91(6):753. doi:10.1136/bjo.2006.110239. Accessed February 19, 2019.
119. Holz FG, Strauss EC, Schmitz-Valckenberg S, van Lookeren Campagne M. Geographic atrophy: clinical features and potential therapeutic approaches. *Ophthalmology*. 2014;121(5):1079-1091. doi:10.1016/j.ophtha.2013.11.023. Accessed September 28, 2018.
120. Leat SJ, Fengqin Si F, Gold D, Pickering D, Gordon K, Hodge W. The Experience of a Randomized Clinical Trial of Closed-Circuit Television Versus Eccentric Viewing Training for People with Age-Related Macular Degeneration. *Journal of Visual Impairment & Blindness*. 2017;111(4):354-368. doi:10.1177/0145482X1711100405. Accessed July 28, 2018.
121. Cheung N, Mitchell P, Wong TY. Diabetic retinopathy. *Lancet*. 2010 Jul 10; 376(9735):124-36. doi:10.1016/S0140-6736(09)62124-3. Accessed November 13, 2018.
122. Aiello LM. Perspectives on diabetic retinopathy. *American Journal of Ophthalmology*. 2003;136(1):122-135. doi:https://doi.org/10.1016/S0002-9394(03)00219-8.
123. Lee R, Wong TY, Sabanayagam C. Epidemiology of diabetic retinopathy, diabetic macular edema and related vision loss. *Eye Vis (Lond)*. 2015;2(17). doi: 10.1186/s40662-015-0026-2. Accessed January 20, 2019.
124. Sabanayagam C, Yip W, Ting DSW, Tan G, Wong TY. Ten Emerging Trends in the Epidemiology of Diabetic Retinopathy. *Ophthalmic Epidemiology*. 2016;23(4):209-222. doi:10.1080/09286586.2016.1193618. Accessed January 22, 2019.
125. The Eye Diseases Prevalence Research Group. The Prevalence of Diabetic Retinopathy Among Adults in the United States. *Arch Ophthalmol*. 2004;122(4):552-563. doi:10.1001/archophth.122.4.552. Accessed February 20, 2019.
126. Zhang X, Saaddine JB, Chou C, Cotch MF, Cheng YJ, Geiss LS, et al. Prevalence of Diabetic Retinopathy in the United States, 2005–2008. *JAMA*. 2010; 304(6): 649–656. doi:10.1001/jama.2010.1111. Accessed November 18, 2018.
127. Roy MS1, Klein R, O'Colmain BJ, Klein BE, Moss SE, Kempen JH. The prevalence of diabetic retinopathy among adult type 1 diabetic persons in the United States. *Arch Ophthalmol*. 2004;122(4):546-51. doi:10.1001/archophth.122.4.546. Accessed January 18, 2019.
128. Wong TY1, Klein R, Islam FM, Cotch MF, Folsom AR, Klein BE, Sharrett AR, Shea S. Diabetic retinopathy in a multi-ethnic cohort in the United States. *Am J Ophthalmol*. 2006 Mar;141(3):446-455. doi:10.1016/j.ajo.2005.08.063. Accessed December 5, 2018.
129. Shani M, Eviatar T, Komaneshter D, Vinker S. Diabetic retinopathy -incidence and risk factors in a community setting-a longitudinal study. *Scandinavian Journal of Primary Health Care*. 2018;36(3):237-241. doi:10.1080/02813432.2018.1487524.
130. Stratton IM, Kohner EM, Aldington SJ, et al. for the UKPDS Group: UKPDS 50: Risk factors for incidence and progression of retinopathy in Type II diabetes over 6 years from diagnosis. *Diabetologia*. 2001;44:156–163.
131. Martín-Merino E, Fortuny J, Rivero-Ferrer E, et al. Incidence of retinal complications in a cohort of newly diagnosed diabetic patients. *PLoS One*. 2014;9:e100283.
132. Cikamatana L1, Mitchell P, Rochtchina E, Foran S, Wang JJ. Five-year incidence and progression of diabetic retinopathy in a defined older population: the Blue Mountains Eye

- Study. *Eye (Lond)*. 2007 Apr;21(4):465-71. doi:10.1038/sj.eye.6702771. Accessed February 20, 2019.
133. Rossing P. The changing epidemiology of diabetic microangiopathy in type 1 diabetes. *Diabetologia*. 2005 Aug;48(8):1439-44. doi:10.1007/s00125-005-1836-x Accessed January 22, 2019.
134. Klein R, Klein BE. Epidemiology of ocular functions and diseases in persons with diabetes. In: Barrett-Conner E, Becker DJ, Boyko EJ, et al. *Diabetes in America*. 3rd Ed. Bethesda, MD: National Institute of Health; 2018. <https://www.niddk.nih.gov/about-niddk/strategic-plans-reports/diabetes-in-america-3rd-edition#suggest>. Accessed February 20, 2019.
135. Gupta A, Delhiwala KS, Raman RPG, Sharma T, Srinivasan S, Kulothungan V. Failure to initiate early insulin therapy - A risk factor for diabetic retinopathy in insulin users with Type 2 diabetes mellitus: Sankara Nethralaya-Diabetic Retinopathy Epidemiology and Molecular Genetics Study (SN-DREAMS, Report number 35). *Indian Journal of Ophthalmology*. 2016;64(6):440-445. doi:10.4103/0301-4738.187668. Accessed January 21, 2019.
136. Lecaire T, Palta M, Zhang H, Allen C, Klein R, D'Alessio D. Lower-than-expected prevalence and severity of retinopathy in an incident cohort followed during the first 4-14 years of type 1 diabetes: the Wisconsin Diabetes Registry Study. *Am J Epidemiol*. 2006;164(2):143. doi:10.1093/aje/kwj166. Accessed January 21, 2019.
137. Cai X, Chen Y, Yang W, Gao X, Han X, Ji L. The association of smoking and risk of diabetic retinopathy in patients with type 1 and type 2 diabetes: a meta-analysis. *Endocrine*. 2018;62(2):299-306. doi:10.1007/s12020-018-1697-y. Accessed January 21, 2019.
138. Brown JB1, Pedula KL, Summers KH. Diabetic retinopathy: contemporary prevalence in a well-controlled population. *Diabetes Care*. 2003 Sep;26(9):2637-42. <https://doi.org/10.2337/diacare.26.9.2637>. Accessed December 5, 2018.
139. Fraser CE, D'Amico DJ. Diabetic retinopathy: classification and clinical features. UptoDate. https://www.uptodate.com/contents/diabetic-retinopathy-classification-and-clinical-features?search=diabetic%20retinopathy&source=search_result&selectedTitle=1~145&u_sage_type=default&display_rank=1#H7. Updated October 2, 2018. Accessed February 20, 2019.
140. Damkondwar DR, Raman R, Suganeswari G, Kulothungan V, Sharma T. Assessing Framingham cardiovascular risk scores in subjects with diabetes and their correlation with diabetic retinopathy. *Indian Journal of Ophthalmology*. 2012;60(1):45-48. <http://pointloma.idm.oclc.org/login?url=http://search.ebscohost.com/login.aspx?direct=true&db=rzh&AN=104624020&site=ehost-live>. Accessed January 21, 2019.
141. Tan NYQ, Chew M, Tham Y-C, et al. Associations between sleep duration, sleep quality and diabetic retinopathy. *Plos One*. 2018;13(5):e0196399. doi:10.1371/journal.pone.0196399. January 21, 2019.
142. Jee D, Keum N, Kang S, Arroyo JG. Sleep and diabetic retinopathy. *Acta Ophthalmologica*. 2017;95(1):41-47. doi:10.1111/aos.13169. January 21, 2019.
143. Mathebula SD. How diabetics lose vision: Molecular and biochemical mechanisms associated with hyperglycaemic damage in the retina. *African Journal for Physical, Health Education, Recreation & Dance*. 2015;21(3:1):819-834.

- <http://pointloma.idm.oclc.org/login?url=http://search.ebscohost.com/login.aspx?direct=true&db=s3h&AN=110326557&site=ehost-live>. Accessed February 21, 2019.
144. Nathan DM, Genuth S, Lachin J, Cleary P, Crofford O, Davis M, Rand L, Siebert C. The effect of intensive treatment of diabetes on the development and progression of long-term complications in insulin-dependent diabetes mellitus. *N Engl J Med*. 1993 Sep 30;329(14):977-86. doi:10.1056/NEJM199309303291401. Accessed February 20, 2019.
145. UK Prospective Diabetes Study (UKPDS) Group. Intensive blood-glucose control with sulphonylureas or insulin compared with conventional treatment and risk of complications in patients with type 2 diabetes (UKPDS 33). *Lancet*. 1998;352(9131):837. [https://doi.org/10.1016/S0140-6736\(98\)07019-6](https://doi.org/10.1016/S0140-6736(98)07019-6). Accessed February 20, 2019.
146. Nyengaard JR1, Ido Y, Kilo C, Williamson JR. Interactions between hyperglycemia and hypoxia: implications for diabetic retinopathy. *Diabetes*. 2004;53(11):2931-8. <https://doi.org/10.2337/diabetes.53.11.2931>. Accessed February 20, 2019.
147. Yeh PT, Yang CM, Huang JS, Chien CT, Yang CH, Chiang YH, Shih YF. Vitreous levels of reactive oxygen species in proliferative diabetic retinopathy. *Ophthalmology*. 2008;115(4):734. doi:10.1016/j.optha.2007.05.041. Accessed February 20, 2019.
148. Hoang-Ton Nguyen, van Duinkerken E, Verbraak FD, et al. Retinal blood flow is increased in type 1 diabetes mellitus patients with advanced stages of retinopathy. *BMC Endocrine Disorders*. 2016;16:1-9. doi:10.1186/s12902-016-0105-y. Accessed February 20, 2019.
149. Guan K, Hudson C, Wong T, et al. Retinal hemodynamics in early diabetic macular edema. *Diabetes*. 2006;55(3):813-818. <http://pointloma.idm.oclc.org/login?url=http://search.ebscohost.com/login.aspx?direct=true&db=rzh&AN=106316002&site=ehost-live>. Accessed February 21, 2019.
150. Khuu L-A, Tayyari F, Sivak JM, et al. Aqueous humour concentrations of TGF- β , PLGF and FGF-1 and total retinal blood flow in patients with early non-proliferative diabetic retinopathy. *Acta Ophthalmologica*. 2017;95(3):e206-e211. doi:10.1111/aos.13230. December 18, 2018.
151. Hammes H-P, Du X, Edelstein D, et al. Benfotiamine blocks three major pathways of hyperglycemic damage and prevents experimental diabetic retinopathy. *Nature Medicine*. 2003;9(3):294. doi:10.1038/nm834. Accessed December 29, 2018.
152. Tsai T, Kuehn S, Tsiampalis N, et al. Anti-inflammatory cytokine and angiogenic factors levels in vitreous samples of diabetic retinopathy patients. *PLoS ONE*. 2018;13(3):1-13. doi:10.1371/journal.pone.0194603. Accessed December 29, 2018.
153. Gao BB, Clermont A, Rook S, Fonda SJ, Srinivasan VJ, Wojtkowski M, Fujimoto JG, Avery RL, Arrigg PG, Bursell SE, Aiello LP, Feener EP. Extracellular carbonic anhydrase mediates hemorrhagic retinal and cerebral vascular permeability through prekallikrein activation. *Nature Medicine*. 2007;13(2):181. doi:10.1038/nm1534. Accessed December 29, 2018.
154. Bressler SB, Quigley HA, Schein OD. Symptoms of Diabetic Retinopathy. *Vision*. January 2009:53-54. <http://pointloma.idm.oclc.org/login?url=http://search.ebscohost.com/login.aspx?direct=true&db=hxh&AN=44639698&site=ehost-live>. Accessed February 22, 2019.
155. Diabetic macular edema.; 2010. <http://www.nih.gov/researchmatters/may2010/05102010eye.htm>. Accessed March 16, 2019.

156. Proliferative retinopathy.
https://commons.wikimedia.org/wiki/File:Fundus_Proliferative_retinopathy_EDA01.JPG
. Accessed March 16, 2019.
157. Mohamed Q, Gillies MC, Wong TY. Management of Diabetic Retinopathy. *Jama*. 2007;298(8):902-916. doi:10.1001/jama.298.8.902. Accessed December 20, 2018.
158. Poulaki V, Qin W, Jousen AM, et al. Acute intensive insulin therapy exacerbates diabetic blood-retinal barrier breakdown via hypoxia-inducible factor-1 α and VEGF. *Journal of Clinical Investigation*. 2002;109(6):805-815. doi:10.1172/jci13776.
159. Shi R, Zhao L, Wang F, et al. Effects of lipid-lowering agents on diabetic retinopathy: a Meta-analysis and systematic review. *International Journal Of Ophthalmology*. 2018;11(2):287-295. doi:10.18240/ijo.2018.02.18. Accessed January 5, 2019.
160. Lovestam-Adrian M, Agardh C-D, Torffvit O, Agardh E. Type 1 diabetes patients with severe non-proliferative retinopathy may benefit from panretinal photocoagulation. *Acta Ophthalmologica Scandinavica*. 2003;81(3):221-225. doi:10.1034/j.1600-0420.2003.00050.x. Accessed January 2, 2019.
161. Early Treatment Diabetic Retinopathy Study Research Group Early photocoagulation for diabetic retinopathy. ETDRS report number 9. *Ophthalmology*. 1991;98(5):766-785. doi:10.1016/s0161-6420(13)38011-7.
162. Gross JG, Glassman AR, Liu D, et al. Five-Year Outcomes of Panretinal Photocoagulation vs Intravitreal Ranibizumab for Proliferative Diabetic Retinopathy. *JAMA Ophthalmology*. 2018;136(10):1138-1148. doi:10.1001/jamaophthalmol.2018.3255. Accessed January 19, 2019.
163. Early Vitrectomy for Severe Vitreous Hemorrhage in Diabetic Retinopathy. *Archives of Ophthalmology*. 1990;108(7):958-964. doi:10.1001/archophth.1990.01070090060040.
164. Klein R, Knudtson MD, Lee KE, Gangnon R, Klein BE. The Wisconsin Epidemiologic Study of Diabetic Retinopathy XXII. The Twenty-Five-Year Progression of Retinopathy in Persons with Type 1 Diabetes. *Ophthalmology*. 2008;115(11):1859-868. doi:10.1016/j.ophtha.2008.08.023. Accessed November 20, 2018.
165. Morrison JL, Hodgson LA, Lim LL, Al-Qureshi S. Diabetic retinopathy in pregnancy: a review. *Clinical & Experimental Ophthalmology*. 2016;44(4):321-334. doi:10.1111/ceo.12760. Accessed February 22, 2019.
166. Krachmer JH. Pellucid Marginal Corneal Degeneration. *Archives of Ophthalmology*. 1978;96(7):1217-1221. doi:10.1001/archophth.1978.03910060051009. Accessed January 20, 2019.
167. Jinabhai A, Radhakrishnan H, O'Donnell C. Pellucid corneal marginal degeneration: A review. *Contact Lens & Anterior Eye*. 2011;34(2):56-63. doi:10.1016/j.clae.2010.11.007. Accessed January 20, 2019.
168. Kennedy RH, Bourne WM, Dyer JA. A 48-Year Clinical and Epidemiologic Study of Keratoconus. *American Journal of Ophthalmology*. 1986;101(3):267-273. doi:10.1016/0002-9394(86)90817-2. Accessed January 21, 2019.
169. Godefrooij DA, de Wit GA, Uiterwaal CS, Imhof SM, Wisse RP. Age-specific Incidence and Prevalence of Keratoconus: A Nationwide Registration Study. *American journal of ophthalmology*. 2017;175:169-72. doi:2017/01/01. pmid:28039037. Accessed January 21, 2019.

170. Georgiou T, Funnell CL, Cassels-Brown A, Oconor R. Influence of ethnic origin on the incidence of keratoconus and associated atopic disease in Asians and white patients. *Eye*. 2004;18(4):379-383. doi:10.1038/sj.eye.6700652. Accessed January 20, 2019.
171. Woodward MA, Blachley TS, Stein JD. The Association Between Sociodemographic Factors, Common Systemic Diseases, and Keratoconus. *Ophthalmology*. 2016;123(3):457-465. doi:10.1016/j.ophtha.2015.10.035. Accessed January 22, 2019.
172. Tzelikis PF, Cohen EJ, Rapuano CJ, Hammersmith KM, Laibson PR. Management of Pellucid Marginal Corneal Degeneration. *Cornea*. 2005;24(5):555-560. doi:10.1097/01.ico.0000153555.82278.5b. Accessed January 22, 2019.
173. Randleman JB1, Woodward M, Lynn MJ, Stulting RD. Risk assessment for ectasia after corneal refractive surgery. *Ophthalmology*. 2008;115(1):37-50. doi:10.1016/j.ophtha.2007.03.073. Accessed February 16, 2019.
174. Balasubramanian SA, Pye DC, Willcox MD. Effects of eye rubbing on the levels of protease, protease activity and cytokines in tears: relevance in keratoconus. *Clinical & Experimental Optometry*. 2013;96(2):214-218. doi:10.1111/cxo.12038. Accessed February 24, 2019.
175. Wagner H, Barr JT, Zadnik K. Collaborative Longitudinal Evaluation of Keratoconus (CLEK) Study: Methods and Findings to Date. *Cont Lens Anterior Eye*. 2007 Sep; 30(4): 223–232. doi: 10.1016/j.clae.2007.03.001. Accessed February 24, 2019.
176. Weed KH, Macewen CJ, Giles T, Low J, McGhee CN. The Dundee University Scottish Keratoconus study: demographics, corneal signs, associated diseases, and eye rubbing. *Eye*. 2008;22(4):534-541. <http://pointloma.idm.oclc.org/login?url=http://search.ebscohost.com/login.aspx?direct=true&db=rzh&AN=105701162&site=ehost-live>. Accessed February 24, 2019.
177. Sharma N, Rao K, Maharana PK, Vajpayee RB. Ocular allergy and keratoconus. *Indian J Ophthalmol*. 2013;61:407-9. doi:10.4103/0301-4738.116063. Accessed February 23, 2019.
178. Wang Y, Rabinowitz YS, Rotter JI & Yang H. Genetic epidemiological study of keratoconus: evidence for major gene determination. *Am J Med Genet*. 2000;93(5): 403–409. [https://doi.org/10.1002/1096-8628\(20000828\)93:5<403::AID-AJMG11>3.0.CO;2-A](https://doi.org/10.1002/1096-8628(20000828)93:5<403::AID-AJMG11>3.0.CO;2-A). Accessed February 16, 2019.
179. Kayazawa F, Nishimura K, Kodama Y, Tsuji T, Itoi M. Keratoconus with pellucid marginal corneal degeneration. *Archives Of Ophthalmology* (Chicago, Ill: 1960). 1984;102(6):895-896. <http://pointloma.idm.oclc.org/login?url=http://search.ebscohost.com/login.aspx?direct=true&db=mnh&AN=6610406&site=ehost-live>. Accessed February 6, 2019.
180. Randleman JB, Woodward M, Lynn MJ, Stulting RD. Risk Assessment for Ectasia after Corneal Refractive Surgery. *Ophthalmology*. 2008;115(1):37-50. doi:10.1016/j.ophtha.2007.03.073. Accessed February 6, 2019.
181. Abdelkader A, Esquenazi S, Shihadeh W, et al. Healing Process at the Flap Edge in Its Influence in the Development of Corneal Ectasia After LASIK. *Current Eye Research*. 2006;31(11):903-908. doi:10.1080/02713680600954278. Accessed February 6, 2019.
182. Ambrósio R Jr, Dawson DG, Salomão M, Guerra FP, Caiado ALC, Belin MW. Corneal ectasia after LASIK despite low preoperative risk: tomographic and biomechanical findings in the unoperated, stable, fellow eye. *Journal Of Refractive Surgery* (Thorofare,

- NJ: 1995). 2010;26(11):906-911. doi:10.3928/1081597X-20100428-02. Accessed February 6, 2019.
183. Vazirani J, Basu S. Keratoconus: current perspectives. *Clinical Ophthalmology*. 2013;7:2019-2030. doi:10.2147/opth.s50119. Accessed February 7, 2019.
184. Nielsen K, Hjortdal J, Pihlmann M, Corydon TJ. Update on the keratoconus genetics. *Acta Ophthalmologica*. 2012;91(2):106-113. doi:10.1111/j.1755-3768.2012.02400.x. Accessed February 7, 2019.
185. Parker DL, McDonnell PJ, Barraquer J, Green WR. Pellucid Marginal Corneal Degeneration. *Cornea*. 1986;5(2):115-124. doi:10.1097/00003226-198605020-00007. Accessed February 10, 2019.
186. Keratoconus with Munson's sign.; 2008.
<https://commons.wikimedia.org/wiki/File:Keratoconus-with-Munsons-sign-USA-1965.jpg>. Accessed March 15, 2019.
187. Martínez-Abad A, Piñero DP. Pellucid marginal degeneration: Detection, discrimination from other corneal ectatic disorders and progression. *Contact Lens & Anterior Eye: The Journal Of The British Contact Lens Association*. 2018. doi:10.1016/j.clae.2018.11.010.
188. Panos GD, Hafezi F, Gatzoufas Z. Pellucid marginal degeneration and keratoconus; Differential diagnosis by corneal topography. *Journal of Cataract & Refractive Surgery*. 2013;39(6):968. doi:10.1016/j.jcrs.2013.04.020. Accessed February 10, 2019.
189. Hovanesian JA. Hybrid lens improves visual acuity in eyes with keratoconus and pellucid marginal degeneration. *Ocular Surgery News*. 2010;28(6):20. <http://pointloma.idm.oclc.org/login?url=http://search.ebscohost.com/login.aspx?direct=true&db=rzh&AN=105155465&site=ehost-live>. Accessed January 31, 2019.
190. Gordon MO, Steger-May K, Szczotka-Flynn L, et al. Baseline Factors Predictive of Incident Penetrating Keratoplasty in Keratoconus. *American Journal of Ophthalmology*. 2006;142(6):923-930. doi:10.1016/j.ajo.2006.07.026. Accessed January 20, 2019.
191. Jabbarvand M, Hashemian H, Khodaparast M, Bazvand F, Beheshtnejad A. Outcome of complete intrastromal ring implantation using femtosecond laser in pellucid marginal degeneration. *Eye*. 2015;29(6):783-790. doi:10.1038/eye.2015.33. Accessed January 19, 2019.
192. Tunc Z, Helvacioğlu F, Sencan S. Evaluation of intrastromal corneal ring segments for treatment of post-LASIK ectasia patients with a mechanical implantation technique. *Indian Journal Of Ophthalmology*. 2011;59(6):437-443. doi:10.4103/0301-4738.86310. Accessed January 19, 2019.
193. Keane M, Coster D, Ziaei M, Williams K. Deep anterior lamellar keratoplasty versus penetrating keratoplasty for treating keratoconus. *Cochrane Database of Systematic Reviews*. 2014;(7). doi:10.1002/14651858.cd009700.pub2. Accessed January 20, 2019.
194. Al-Mohaimed MM. Penetrating Keratoplasty for Keratoconus : Visual and Graft Survival Outcomes. *International Journal of Health Sciences*. 2013;7(1):67-74. doi:10.12816/0006023. Accessed January 20, 2019.
195. Kubaloglu A, Sari ES, Unal M, et al. Long-term results of deep anterior lamellar keratoplasty for the treatment of keratoconus. *American Journal Of Ophthalmology*. 2011;151(5):760-767.e1. doi:10.1016/j.ajo.2010.11.020. Accessed January 20, 2019.
196. Kodavoor SK, Deb B, Ramamurthy D. Outcome of deep anterior lamellar keratoplasty patients with intraoperative Descemet's membrane perforation: A retrospective cross-

- sectional study. *Indian Journal Of Ophthalmology*. 2018;66(11):1574-1579. doi:10.4103/ijo.IJOpass:[_]282_18. Accessed January 20, 2019.
- 197.Hersh PS, Stulting RD, Muller D, et al. United States Multicenter Clinical Trial of Corneal Collagen Crosslinking for Keratoconus Treatment. *Ophthalmology*. 2017;124(9):1259-1270. doi:10.1016/j.ophtha.2017.03.052. Accessed January 20, 2019.
- 198.Mastropasqua L. Collagen cross-linking: when and how? A review of the state of the art of the technique and new perspectives. *Eye and Vision*. 2015;2(1). doi:10.1186/s40662-015-0030-6. Accessed January 20, 2019.
- 199.Sharif R, Fowler B, Karamichos D. Collagen cross-linking impact on keratoconus extracellular matrix. *Plos One*. 2018;13(7). doi:10.1371/journal.pone.0200704. Accessed January 20, 2019.
- 200.Stojanovic A, Zhang J, Chen X, Nitter TA, Chen S, Wang Q. Topography-guided transepithelial surface ablation followed by corneal collagen cross-linking performed in a single combined procedure for the treatment of keratoconus and pellucid marginal degeneration. *Journal Of Refractive Surgery* (Thorofare, NJ: 1995). 2010;26(2):145-152. doi:10.3928/1081597X-20100121-10. Accessed February 24, 2019.
- 201.Wong TY, Mitchell P. Hypertensive Retinopathy. *N Engl J Med*. 2004;351:2310-2317. doi:10.1056/NEJMra032865. Accessed August 16, 2018.
- 202.Stryjewski TP, Papakostas TD, Elliott D. Multimodal Imaging of Elschnig Spots: A Case of Simultaneous Hypertensive Retinopathy, Choroidopathy, and Neuropathy. *Seminars In Ophthalmology*. 2017;32(4):397-399. doi:10.3109/08820538.2015.1115091.
- 203.Bakhda RN. Clinical study of fundus findings in pregnancy induced hypertension. *Journal Of Family Medicine And Primary Care*. 2016;5(2):424-429. <http://pointloma.idm.oclc.org/login?url=http://search.ebscohost.com/login.aspx?direct=true&db=mnh&AN=27843854&site=ehost-live>. Accessed February 27, 2019.
- 204.Wong TY, McIntosh R. Hypertensive retinopathy signs as risk indicators of cardiovascular morbidity and mortality. *British Medical Bulletin*. 2005;73(1):57-70. <https://doi.org/10.1093/bmb/ldh050>. Accessed August 16, 2018.
- 205.Mondal RN, Matin MA, Rani M, et al. Prevalence and Risk Factors of Hypertensive Retinopathy in Hypertensive Patients. *Journal of Hypertension: Open Access*. 2017;06(02). doi:10.4172/2167-1095.1000241. Accessed February 25, 2019.
- 206.Wong TY, Klein R, Duncan BB, Nieto FJ, Klein BE, Couper DJ, Hubbard LD, Sharrett AR. Racial differences in the prevalence of hypertensive retinopathy. *Hypertension*. 2003;41(5):1086-91. doi:10.1161/01.HYP.0000064181.63546.53. February 22, 2019.
- 207.Zhang Y, Zhao L, Hongyang L, Yanling W. Risk factors for hypertensive retinopathy in a Chinese population with hypertension: The Beijing Eye study. *Exp Ther Med*. 2019 Jan; 17(1): 453–458. doi:10.3892/etm.2018.6967. Accessed February 25, 2019.
- 208.Hammond S, Wells JR, Marcus DM, Prisant LM. Ophthalmoscopic findings in malignant hypertension. *Journal Of Clinical Hypertension (Greenwich, Conn)*. 2006;8(3):221-223. <http://pointloma.idm.oclc.org/login?url=http://search.ebscohost.com/login.aspx?direct=true&db=mnh&AN=16523002&site=ehost-live>. Accessed February 26, 2019.
- 209.Li G, Shih YI, Kiel JW, De La Garza B, Du F, Duong TQ. MRI Study of Cerebral, Retinal and Choroidal Blood Flow Responses to Acute Hypertension. *Exp Eye Res*. 2013;112:118-124. doi:10.1016/j.exer.2013.04.003. Accessed February 24, 2019.

210. Wong YT, Klein R, Sharrett RA, Duncan BB, Couper DJ, Tielsch JM, Klein BE, Hubbard LD. Retinal arteriolar narrowing and risk of coronary heart disease in men and women the atherosclerosis risk in communities study. *JAMA*. 2002;287(9):1153-1159. doi:10.1001/jama.287.9.1153. Accessed February 25, 2019.
211. Karaca M, Coban E, Felek R, Unal M. The association of oxidative stress with hypertensive retinopathy. *Clinical And Experimental Hypertension (New York, NY: 1993)*. 2013;35(1):16-19. doi:10.3109/10641963.2012.685535. Accessed February 25, 2019.
212. Coban E, Nizam I, Topal C, Akar Y. The association of low-grade systemic inflammation with hypertensive retinopathy. *Clinical And Experimental Hypertension (New York, NY: 1993)*. 2010;32(8):528-531. doi:10.3109/10641963.2010.496519. Accessed February 25, 2019.
213. Coban E, Adanir H, Bilgin D. The association of mean platelet volume levels with hypertensive retinopathy. *Platelets*. 2008;19(2):115-118. <http://pointloma.idm.oclc.org/login?url=http://search.ebscohost.com/login.aspx?direct=true&db=mnh&AN=17852776&site=ehost-live>. Accessed February 26, 2019.
214. Mehta S. Hypertensive Retinopathy. Merck Manuel. <https://www.merckmanuals.com/professional/eye-disorders/retinal-disorders/hypertensive-retinopathy>. Accessed February 24, 2019.
215. Handor H, Daoudi R. Images in clinical medicine. Hypertensive retinopathy associated with preeclampsia. *The New England Journal Of Medicine*. 2014;370(8):752. doi:10.1056/NEJMicm1306891.
216. Hypertensive retinopathy.; 2009. https://commons.wikimedia.org/wiki/File:Hypertensive_retinopathy.jpg. Accessed March 17, 2019.
217. Ong YT, Wong TY, Klein R, Klein BE, Mitchell P, Sharrett AR, Couper DJ, Ikram MK. Hypertensive Retinopathy and Risk of Stroke. *Hypertension*. 2013;62(4):7-6-711. doi:10.1161/HYPERTENSIONAHA.113.01414. Accessed February 14, 2019.
218. Oh KT. Ophthalmic Manifestations of Hypertension. Medscape. <https://emedicine.medscape.com/article/1201779-overview#a3>. Updated September 20, 2018. Accessed February 24, 2019.
219. Rosenthal JM, Johnson MW. Management of Retinal Diseases in Pregnant Patients. *Journal Of Ophthalmic & Vision Research*. 2018;13(1):62-65. doi:10.4103/jovr.jovrpass:[_]195_17. Accessed February 26, 2019.
220. Kolman SAM, van Sijl AM, van der Sluijs FA, van de Ree MA. Consideration of hypertensive retinopathy as an important end-organ damage in patients with hypertension. *Journal Of Human Hypertension*. 2017;31(2):121-125. doi:10.1038/jhh.2016.49.
221. Key statistics for retinoblastoma. American Cancer Society. Updated January 9, 2019. Accessed January 24, 2019.
222. Fernandes AG, Pollock BD, Rabito FA. Retinoblastoma in the United States: A 40-Year Incidence and Survival Analysis. *J Pediatr Ophthalmol Strabismus*. 2018 May 1;55(3):182-188. doi: 10.3928/01913913-20171116-03. Accessed February 28, 2019.
223. Broadus E, Topham A, Singh AD. Incidence of retinoblastoma in the USA: 1975–2004 *British Journal of Ophthalmology*. 2009;93:21-23. doi:10.1136/bjo.2008.138750. Accessed January 22, 2019.

224. Abramson DH, Frank CM, Susman M, Whalen MP, Dunkel IJ, Boyd NW. Presenting signs of retinoblastoma. *J Pediatr.* 1998;132(3 Pt 1):505. [https://doi.org/10.1016/S0022-3476\(98\)70028-9](https://doi.org/10.1016/S0022-3476(98)70028-9). Accessed January 15, 2019.
225. de Jong MC, Kors WA, de Graaf P, Castelijns JA, Moll AC, Kivelä T. The Incidence of Trilateral Retinoblastoma: A Systematic Review and Meta-Analysis. *American Journal Of Ophthalmology.* 2015;160(6):1116-1126.e5. doi:10.1016/j.ajo.2015.09.009. Accessed February 25, 2019.
226. Rosser E, Mandeep SS. Germline retinoblastoma: estimating risk and counseling the family. *Community Eye Health.* 2018;31(101):8-9. <https://www.ncbi.nlm.nih.gov/pmc/articles/PMC5998395/>. Accessed February 27, 2019.
227. Dimaras H, Corson Tw, Corbrinik D, White A, Zhao J, Munier FL. Retinoblastoma. *Nat Rev Dis Primers.* 2015;1:15021. doi:10.1038/nrdp.2015.21. Accessed February 27, 2019.
228. Knudson AG. Mutation and cancer: statistical study of retinoblastoma. *Proc Natl Acad Sci USA.* 1971;68(4):820-3. doi: <https://www.ncbi.nlm.nih.gov/pmc/articles/PMC389051/>. Accessed February 28, 2019.
229. Parma D, Ferrer M, Luce L, Giliberto F, Szijan I. RB1 gene mutations in Argentine retinoblastoma patients. Implications for genetic counseling. *PLoS ONE.* 2017;12(12):1-12. doi:10.1371/journal.pone.0189736. Accessed February 28, 2019.
230. Ayari Jeridi H, Bouguila H, Ansperger-Rescher B, Baroudi O, Mdimegh I, Omran I, et al. Genetic testing in Tunisian families with heritable retinoblastoma using a low cost approach permits accurate risk prediction in relatives and reveals incomplete penetrance in adults. *Exp Eye Res.* 2014;124:48–55. Accessed February 28, 2019.
231. Rushlow DE, Mol BM, Kennett JY, Yee S, Pajovic BL, et al. Characterization of retinoblastomas without RB1 mutations: genomic, gene expression, and clinical studies. *The Lancet.* 2013;14(4):327-334. doi:[https://doi.org/10.1016/S1470-2045\(13\)70045-7](https://doi.org/10.1016/S1470-2045(13)70045-7). Accessed February 28, 2019.
232. Shetty OA, Naresh KN, Banavali SD, et al. Evidence for the presence of high risk human papillomavirus in retinoblastoma tissue from nonfamilial retinoblastoma in developing countries. *Pediatric Blood & Cancer.* 2012;58(2):185-190. doi:10.1002/pbc.23346.
233. Munger K, Jones DL. Human papillomavirus carcinogenesis: an identity crisis in the retinoblastoma tumor suppressor pathway. *Journal Of Virology.* 2015;89(9):4708-4711. doi:10.1128/JVI.03486-14.
234. Abramson DH, Frank CM, Susman M, Whalen MP, Dunkel AJ, Boyd WN. Presenting signs of retinoblastoma. *Journal of Pediatrics.* 1998;132(3):505-508. doi:[https://doi.org/10.1016/S0022-3476\(98\)70028-9](https://doi.org/10.1016/S0022-3476(98)70028-9). Accessed December 7, 2018.
235. Aerts, I, Lumbroso-Le Rouic, L, Marion Gauthier-Villars, M, Brisse, H, Doz, F, Desjardins, L. Retinoblastoma. *Orphanet Journal of Rare Diseases.* 1, 31. 2006. PMID 16934146. doi: 10.1186/1750-1172-1-31 (<http://www.ojrd.com/content/1/1/31>)
236. Abramson DH, Beaverson K, Sangani P, Vora RA, Lee TC, Hochberg HM, Kirsztrot J, Ranjithan. Screening for retinoblastoma: presenting signs as prognosticators of patient and ocular survival. *M Pediatrics.* 2003;112(6 Pt 1):1248. <https://pediatrics.aappublications.org/content/112/6/1248>. Accessed December 8, 2018.
237. Skalet AH, Gombos DS, Gallie BL, Kim JW, Shields CL, Marr BP, Plon SE, Chévez-Barrios P. Screening Children at Risk for Retinoblastoma: Consensus Report from the American Association of Ophthalmic Oncologists and Pathologists. *Ophthalmology.*

- 2018 Mar;125(3):453-458. doi:10.1016/j.ophtha.2017.09.001. Accessed December 9, 2018.
- 238.Noorani HZ, Khan HN, Gallie BL, Detsky AS. Cost comparison of molecular versus conventional screening of relatives at risk for retinoblastoma. *Am J Hum Genet.* 1996;59(2):301–307. <https://www.ncbi.nlm.nih.gov/pmc/articles/PMC1914748/>. Accessed December 9, 2018.
- 239.Fabian ID, Reddy A, Sagoo MS. Classification and staging of retinoblastoma. *Community Eye Health.* 2018;31(101):11-13. <https://www.ncbi.nlm.nih.gov/pmc/articles/PMC5998397/>. Accessed December 8, 2018.
- 240.Chawla B, Jain A, Seth R, Azad R, Mohan VK, Pushker N, Ghose S. Clinical outcome and regression patterns of retinoblastoma treated with systemic chemoreduction and focal therapy: A prospective study. *Indian J Ophthalmol.* 2016;64(7):524–529. doi:10.4103/0301-4738.190143. Accessed February 28, 2019.
- 241.Chawla B, Jain A, Azad R. Conservative treatment modalities in retinoblastoma. *Indian J Ophthalmol.* 2013 Sep; 61(9): 479–485. doi: 10.4103/0301-4738.119424. Accessed December 7, 2018.
- 242.Shields CL, Santos MC, Diniz W, Gündüz K, Mercado G, Cater JR, Shields JA. Thermotherapy for retinoblastoma. *Arch Ophthalmol.* 1999 Jul;117(7):885-93.
- 243.Abramson DH, Ellsworth RM, Rozakis GW. Cryotherapy for retinoblastoma. *Arch Ophthalmol.* 1982;100(8):1253-1256. <https://www.ncbi.nlm.nih.gov/pubmed/7103809>. Accessed December 7, 2018.
- 244.Abramson DH1, Frank CM. Second nonocular tumors in survivors of bilateral retinoblastoma: a possible age effect on radiation-related risk. *Ophthalmology.* 1998;105(4):573-9. doi:10.1016/S0161-6420(98)94006-4. Accessed December 9, 2018.
- 245.Abramson DH, Dunkel IJ, Brodie SE, Kim JW, Gobin YP. A phase I/II study of direct intraarterial (ophthalmic artery) chemotherapy with melphalan for intraocular retinoblastoma initial results. *Ophthalmology.* 2008;115(8):1398-404. doi:10.1016/j.ophtha.2007.12.014. Accessed January 15, 2019.
- 246.Klufas MA, Gobin YP, Marr B, Brodie SE, Dunkel IJ, Abramson DH. Intra-arterial chemotherapy as a treatment for intraocular retinoblastoma: alternatives to direct ophthalmic artery catheterization. *AJNR Am J Neuroradiol.* 2012;33(8):1608-14. doi:10.3174/ajnr.A3019. Accessed January 15, 2019.
- 247.Choi S, Han JW, Kim H, Kim BS, Kim DJ, Lee SC, Lyu CJ. Combined chemotherapy and intra-arterial chemotherapy of retinoblastoma. *Korean J Pediatr.* 2013 Jun;56(6):254-9. doi: 10.3345/kjp.2013.56.6.254. Accessed January 15, 2019.
- 248.Shields CL, Manjandavida FP, Lally SE, Pieretti G, Arepalli SA, Caywood EH, Jabbour P, Shields JA. Intra-arterial chemotherapy for retinoblastoma in 70 eyes: outcomes based on the international classification of retinoblastoma. *Ophthalmology.* 2014;121(7):1453-60. doi: 10.1016/j.ophtha.2014.01.026. Accessed January 15, 2019.
- 249.Gobin YP, Dunkel IJ, Marr BP, Brodie SE, Abramson DH. Intra-arterial chemotherapy for the management of retinoblastoma: four-year experience. *Arch Ophthalmol.* 2011;129(6):732-7. doi:10.1001/archophthalmol.2011.5. Accessed January 15, 2019.
- 250.Ernst Fuch. Fuchs E. Dystrophia epithelialis corneae. *Graefes Arch Clin Exp Ophthalmol.* 1910:478–508. Accessed December 28, 2018.

251. Gain P, Jullienne R, He Z, et al. Global Survey of Corneal Transplantation and Eye Banking. *JAMA Ophthalmology*. 2016;134(2):167-173. doi:10.1001/jamaophthalmol.2015.4776. Accessed December 28, 2018.
252. Cui Z, Zeng Q, Guo Y, et al. Pathological molecular mechanism of symptomatic late-onset Fuchs endothelial corneal dystrophy by bioinformatic analysis. *PLoS ONE*. 2018;13(5):1-15. doi:10.1371/journal.pone.0197750. Accessed December 28, 2018.
253. Ołdak M, Ruszkowska E, Udziela M, et al. Fuchs Endothelial Corneal Dystrophy: Strong Association with rs613872 Not Paralleled by Changes in Corneal Endothelial TCF4 mRNA Level. *BioMed Research International*. 2015;2015:1-6. doi:10.1155/2015/640234.
254. Jurkunas UV, Bitar MS, Funaki T, Azizi B. Evidence of Oxidative Stress in the Pathogenesis of Fuchs Endothelial Corneal Dystrophy. *The American Journal of Pathology*. 2010;177(5):2278-2289. <https://doi.org/10.2353/ajpath.2010.100279>. Accessed February 2, 2019.
255. Engler C, Kelliher C, Spitze AR, et al. Unfolded protein response in fuchs endothelial corneal dystrophy: a unifying pathogenic pathway? *American Journal of Ophthalmology*. 2010;149(2):194-202.e2. doi:10.1016/j.ajo.2009.09.009. Accessed February 3, 2019.
256. Szentmáry N, Szende B, Süveges I. Epithelial Cell, Keratocyte, and Endothelial Cell Apoptosis in Fuchs Dystrophy and in Pseudophakic Bullous Keratopathy. *European Journal of Ophthalmology*. 2005;15(1):17-22. doi:10.1177/112067210501500103. Accessed February 3, 2019.
257. Li QJ. The Role of Apoptosis in the Pathogenesis of Fuchs Endothelial Dystrophy of the Cornea. *Archives of Ophthalmology*. 2001;119(11):1597-1604. doi:10.1001/archophth.119.11.1597. Accessed February 3, 2019.
258. Mittal M, Siddiqui MR, Tran K, Reddy SP, Malik AB. Reactive oxygen species in inflammation and tissue injury. *Antioxid Redox Signal*. 2014;20(7):1126-67. doi:10.1089/ars.2012.5149. Accessed March 2, 2019.
259. Okumura N, Minamiyama R, Ho LT, et al. Involvement of ZEB1 and Snail1 in excessive production of extracellular matrix in Fuchs endothelial corneal dystrophy. *Laboratory Investigation*. 2015;95(11):1291-1304. doi:10.1038/labinvest.2015.111. Accessed February 2, 2019.
260. Gottsch JD, Sundin OH, Lui SH, Jun AS, Broman KW, Stark WJ, et al. Inheritance of a Novel COL8A2 Mutation Defines a Distinct Early-Onset Subtype of Fuchs Corneal Dystrophy. *Investigative Ophthalmology & Visual Science*. 2005;46:1934-1939. doi:10.1167/iovs.04-0937. Accessed March 2, 2019.
261. Hemadevi B, Srinivasan M, Arunkumar J, Prajna NV, Sundaresan P. Genetic analysis of patients with Fuchs endothelial corneal dystrophy in India. *BMC Ophthalmology*. 2010;10(3). doi:10.1186/1471-2415-10-3. Accessed February 2, 2019.
262. Eghrari AO, Gottsch JD. Fuchs' corneal dystrophy. *Expert Rev Ophthalmol*. 2010;5(2):147-159. doi:10.1586/eop.10.8. Accessed February 3, 2019.
263. Leonardo CC, Pennypacker KR. Fuch's Corneal Dystrophy. *Klintworth Orphanet Journal of Rare Diseases*. 2009 4:7 <http://www.ojrd.com/content/4/1/7/figure/F62>. Accessed March 19, 2019.
264. Lovino C, Fossarello M, Giannaccare G, et al. Corneal endothelium features in Fuchs' Endothelial Corneal Dystrophy: A preliminary 3D anterior segment optical coherence

- tomography study. *PLoS ONE*. 2018;13(11):1-12. doi:10.1371/journal.pone.0207891. Accessed February 2, 2019.
265. Price DA, Kelley M, Price FW, Price MO. Five-Year Graft Survival of Descemet Membrane Endothelial Keratoplasty (EK) versus Descemet Stripping EK and the Effect of Donor Sex Matching. *Ophthalmology*. 2018;125(10):1508-1514. doi:10.1016/j.ophtha.2018.03.050. Accessed February 3, 2019.
266. Wacker K, Baratz KH, Maguire LJ, McLaren JW, Patel SV. Descemet Stripping Endothelial Keratoplasty for Fuchs' Endothelial Corneal Dystrophy: Five-Year Results of a Prospective Study. *Ophthalmology*. 2016;123(1):154-160. doi:10.1016/j.ophtha.2015.09.023. Accessed March 3, 2019.
267. Okumura N, Matsumoto D, Fukui Y, et al. Feasibility of cell-based therapy combined with descemetorhexis for treating Fuchs endothelial corneal dystrophy in rabbit model. *PLoS ONE*. 2018;13(1):1-14. doi:10.1371/journal.pone.0191306. Accessed March 3, 2019.
268. Liesegang T. Herpes Zoster Ophthalmicus Natural History, Risk Factors, Clinical Presentation, and Morbidity. *Ophthalmology*. 2008;115(2). doi:10.1016/j.ophtha.2007.10.009. Accessed January 25, 2019.
269. Tran KD, Falcone MM, Choi DS, et al. Epidemiology of Herpes Zoster Ophthalmicus: Recurrence and Chronicity. *Ophthalmology*. 2016;123(7):1469-1475. doi:10.1016/j.ophtha.2016.03.005. Accessed January 25, 2019.
270. Ragozzino MW, Melton LJ, Kurland LT, Chu CP, Perry HO. Population-Based Study of Herpes Zoster and Its Sequelae. *Medicine*. 1982;61(5):310-316. doi:10.1097/00005792-198209000-00003. Accessed January 25, 2019.
271. Watkinson S, Seewoodhary R. Managing the care of patients with herpes zoster ophthalmicus. *Nursing Standard*. 2011;25(39):35-40. <http://pointloma.idm.oclc.org/login?url=http://search.ebscohost.com/login.aspx?direct=true&db=rzh&AN=104803927&site=ehost-live>. Accessed January 25, 2019.
272. John AR, Canaday DH. Herpes Zoster in the Older Adult. *Infectious Disease Clinics of North America*. 2017;31(4):811-826. doi:10.1016/j.idc.2017.07.016. Accessed January 25, 2019.
273. Hales CM, Harpaz R, Joesoef MR, Bialek SR. Examination of Links Between Herpes Zoster Incidence and Childhood Varicella Vaccination. *Annals of Internal Medicine*. 2013;159(11):739-745. doi:10.7326/0003-4819-159-11-201312030-00006. Accessed January 26, 2019.
274. Yawn BP, Wollan PC, Sauver JLS, Butterfield LC. Herpes Zoster Eye Complications: Rates and Trends. *Mayo Clinic Proceedings*. 2013;88(6):562-570. doi:10.1016/j.mayocp.2013.03.014. Accessed January 26, 2019.
275. Nair AP, Al Shemmari S. T cell lymphoma with disseminated herpes zoster on presentation and subsequent recurrence leading to blindness--a case report. *Annals Of Hematology*. 2011;90(9):1119-1121. doi:10.1007/s00277-010-1147-2. Accessed March 4, 2019.
276. Kim MS, Kim DJ, Na CH, Shin BS. A Study of the Changes of T Helper 17 Cells and Regulatory T Cells in Herpes Zoster. *Annals Of Dermatology*. 2017;29(5):578-585. doi:10.5021/ad.2017.29.5.578. Accessed March 4, 2019.

277. Xing Q, Hu D, Shi F, Chen F. Role of regulatory T cells in patients with acute herpes zoster and relationship to postherpetic neuralgia. *Archives of Dermatological Research*. 2013;305(8):715-722. doi:10.1007/s00403-013-1367-0. Accessed March 4, 2019.
278. Steain M, Sutherland JP, Rodriguez M, Cunningham AL, Slobedman B, Abendroth A. Analysis of T Cell Responses during Active Varicella-Zoster Virus Reactivation in Human Ganglia. *J Virol*. 2014;88(5):2704–2716. doi: 10.1128/JVI.03445-13. Accessed March 4, 2019.
279. Vrcek I, Choudhury E, Durairaj V. Herpes Zoster Ophthalmicus: A Review for the Internist. *The American Journal Of Medicine*. 2017;130(1):21-26. doi:10.1016/j.amjmed.2016.08.039. Accessed March 4, 2019.
280. Tomkinson A, Roblin DG, Brown MJ. Hutchinson's sign and its importance in rhinology. *Rhinology*. 1995;33(3):180-182. <http://pointloma.idm.oclc.org/login?url=http://search.ebscohost.com/login.aspx?direct=true&db=mnh&AN=8560175&site=ehost-live>. Accessed January 25, 2019.
281. Heilman J. Herpes zoster ophthalmicus as seen after florescence staining using cobalt blue light.; 2018. <https://commons.wikimedia.org/wiki/File:HerpesZosterOphth.jpg>. Accessed March 18, 2019.
282. Hales CM, Harpaz R, Ortega-Sanchez I, et al. Update on recommendations for use of herpes zoster vaccine. *MMWR Morb Mortal Wkly Rep*. 2014;63(33):729-733. <https://www.cdc.gov/mmwr/preview/mmwrhtml/mm6333a3.htm>. Accessed March 4, 2019.
283. Severson EA, Baratz KH, Hodge DO, Burke JP. Herpes Zoster Ophthalmicus in Olmsted County, Minnesota. *Archives of Ophthalmology*. 2003;121(3):386-390. doi:10.1001/archophth.121.3.386. Accessed January 25, 2019.
284. Herbort CP, Buechi ER, Piguët B, Zografos L, Fitting P. High-dose oral acyclovir in acute herpes zoster ophthalmicus: The end of the corticosteroid era. *Current Eye Research*. 1991;10(sup1):171-175. doi:10.3109/02713689109020375. Accessed January 25, 2019.
285. Borkar DS, Tham VM, Esterberg E, et al. Incidence of Herpes Zoster Ophthalmicus: Results from the Pacific Ocular Inflammation Study. *Ophthalmology*. 2013;120(3):451-456. doi:10.1016/j.ophtha.2012.09.007. Accessed January 26, 2019.
286. Tsai M-C, Cheng W-L, Sheu J-J, et al. Increased risk of dementia following herpes zoster ophthalmicus. *Plos One*. 2017;12(11):e0188490. doi:10.1371/journal.pone.0188490. Accessed January 26, 2019.
287. Vanikieti K, Poonyathalang A, Jindahra P, Cheecharoen P, Patputtipong P, Padungkiatsagul T. Isolated optic neuritis with a concurrent abnormal trigeminal nucleus on imaging: case report of a rare complication of herpes zoster ophthalmicus. *BMC Neurology*. 2018;18(1):165. doi:10.1186/s12883-018-1168-3. Accessed March 4, 2019.
288. Koo EB, Gilbert AL, VanderVeen DK. Treatment of Amblyopia and Amblyopia Risk Factors Based on Current Evidence. *Seminars In Ophthalmology*. 2017;32(1):1-7. doi:10.1080/08820538.2016.1228408. Accessed March 7, 2019.
289. Purves D, Augustine GJ, Fitzpatrick D, et al. *Neuroscience*. 6th ed. New York, NY: Oxford University Press; 2018.
290. Magdalene D, Bhattacharjee H, Choudhury M, et al. Community outreach: An indicator for assessment of prevalence of amblyopia. *Indian Journal Of Ophthalmology*. 2018;66(7):940-944. doi:10.4103/ijo.IJOpass:[_]1335_17. December 17, 2018.

291. Gold RS. Study shows higher prevalence of amblyopia in white preschool-aged children. *Ocular Surgery News*. 2010;28(2):20.
<http://pointloma.idm.oclc.org/login?url=http://search.ebscohost.com/login.aspx?direct=true&db=rzh&AN=105301164&site=ehost-live>. Accessed December 17, 2018.
292. McKean-Cowdin R, Cotter SA, Tarczy-Hornoch K, et al. Prevalence of amblyopia or strabismus in Asian and non-Hispanic white preschool children: multi-ethnic pediatric eye disease study. *Ophthalmology*. 2013;120(10):2117-2124.
doi:10.1016/j.ophtha.2013.03.001. Accessed December 17, 2018.
293. Prevalence of amblyopia and strabismus in African American and Hispanic children ages 6 to 72 months the multi-ethnic pediatric eye disease study. *Ophthalmology*. 2008;115(7):1229-1236. doi:10.1016/j.ophtha.2007.08.001. Accessed December 17, 2018.
294. Friedman DS, Repka MX, Katz J, et al. Prevalence of amblyopia and strabismus in white and African American children aged 6 through 71 months the Baltimore Pediatric Eye Disease Study. *Ophthalmology*. 2009;116(11):2128-34.e1-2.
doi:10.1016/j.ophtha.2009.04.034. Accessed December 17, 2018.
295. Ruiz de Zárate B, Tejedor J. Current concepts in the management of amblyopia. *Clin Ophthalmol*. 2007;1(4):403-414. Accessed March 6, 2019.
<https://www.ncbi.nlm.nih.gov/pmc/articles/PMC2704537/>. Accessed March 7, 2019.
296. Stein A, Kelly JP, Weiss AH. Congenital eyelid ptosis: onset and prevalence of amblyopia, associations with systemic disorders, and treatment outcomes. *J Pediatr*. 2014 Oct;165(4):820-4.e2. doi: 10.1016/j.jpeds.2014.06.053. Accessed March 7, 2019.
297. Herd RW, Wood DL. Preschool Vision Screening in Primary Care Pediatric Practice. *Public Health Reports*. 2013;128(3):189-197. doi:10.1177/003335491312800309. Accessed March 7, 2019.
298. Boyd K. What is Ptosis. *American Academy of Ophthalmology*. 2018.
<https://www.aao.org/eye-health/diseases/what-is-ptosis>. Accessed March 7, 2019.
299. US Preventive Services Task Force, Grossman DC, Curry SJ, Owens DK, Barry MJ, Davidson KW, Doubeni CA7, et al. Vision Screening in Children Aged 6 Months to 5 Years: US Preventive Services Task Force Recommendation Statement. *JAMA*. 2017 Sep 5;318(9):836-844. doi: 10.1001/jama.2017.11260. Accessed March 7, 2019.
300. Effect of age using Lea Symbols or HOTV for preschool vision screening. *Optometry & Vision Science*. 2010;87(2):87-95. doi:10.1097/OPX.0b013e3181c750b1. Accessed March 8, 2019.
301. Guimaraes S, Fernandes T, Costa P, Silva E. Should tumbling E go out of date in amblyopia screening? Evidence from a population-based sample normative in children aged 3-4 years. *The British Journal Of Ophthalmology*. 2018;102(6):761-766.
doi:10.1136/bjophthalmol-2017-310691. Accessed March 8, 2019.
302. Kraus CL, Culican SM. New advances in amblyopia therapy I: binocular therapies and pharmacologic augmentation. *The British Journal Of Ophthalmology*. 2018;102(11):1492-1496. doi:10.1136/bjophthalmol-2018-312172. Accessed March 7, 2019.
303. Barollo M, Contemori G, Battaglini L, Pavan A, Casco C. Perceptual learning improves contrast sensitivity, visual acuity, and foveal crowding in amblyopia. *Restorative Neurology And Neuroscience*. 2017;35(5):483-496. doi:10.3233/RNN-170731. Accessed March 7, 2019.

304. Hussain Z, Webb BS, Astle AT, McGraw PV. Perceptual Learning Reduces Crowding in Amblyopia and in the Normal Periphery. *Journal of Neuroscience*. 2012;32(2):474-480. doi:10.1523/JNEUROSCI.3845-11.2012. Accessed March 7, 2019.
305. Kelly KR, Jost RM, Dao L, Beauchamp CL, Leffler JN, Birch EE. Binocular iPad Game vs Patching for Treatment of Amblyopia in Children: A Randomized Clinical Trial. *JAMA Ophthalmology*. 2016;134(12):1402-1408. doi:10.1001/jamaophthalmol.2016.4224. Accessed March 7, 2019.
306. Holmes JM, Manny RE, Lazar EL, et al. A Randomized Trial of Binocular Dig Rush Game Treatment for Amblyopia in Children Aged 7 to 12 Years. *Ophthalmology*. 2019;126(3):456-466. doi:10.1016/j.ophtha.2018.10.032. Accessed March 7, 2019.
307. Daiger SP, Bowne SJ, Sullivan LS. Perspective on Genes and Mutations Causing Retinitis Pigmentosa. *Arch Ophthalmol*. 2007;125(2):151-158. doi:10.1001/archophth.125.2.151. Accessed March 9, 2019.
308. Beales P, Elcioglu N, Woolf A, Parker D, Flinter F. New criteria for improved diagnosis of Bardet-Biedl syndrome: results of a population survey. *J Med Genet*. 1999 Jun; 36(6): 437-446. <https://www.ncbi.nlm.nih.gov/pmc/articles/PMC1734378/>. Accessed March 9, 2019.
309. Anil K, Garip G. Coping strategies, vision-related quality of life, and emotional health in managing retinitis pigmentosa: a survey study. *BMC Ophthalmology*. 2018;18(1):21. doi:10.1186/s12886-018-0689-2. Accessed March 9, 2019.
310. Facts about retinitis pigmentosa. *National Eye Institute*. 2015. https://nei.nih.gov/health/pigmentosa/pigmentosa_facts. Accessed March 9, 2019.
311. Haim M. The epidemiology of retinitis pigmentosa in Denmark. *Acta Ophthalmol Scand Suppl*. 2002;(233):1-34. <https://doi.org/10.1046/j.1395-3907.2002.00001.x>. Accessed March 9, 2019.
312. Birtel J, Gliem M, Mangold E, et al. Next-generation sequencing identifies unexpected genotype-phenotype correlations in patients with retinitis pigmentosa. *PLoS ONE*. 2018;13(12):1-18. doi:10.1371/journal.pone.0207958. Accessed March 11, 2019.
313. Tsujikawa M, Wada Y, Sukegawa M, et al. Age at onset curves of retinitis pigmentosa. *Archives Of Ophthalmology (Chicago, Ill: 1960)*. 2008;126(3):337-340. doi:10.1001/archophth.126.3.337. Accessed March 9, 2019.
314. Anasagasti A, Irigoyen C, Barandika O, de Munain AL, Ruiz-Ederra J. Current mutation discovery approaches in Retinitis Pigmentosa. *Vision Research*. 2012;75:117-129. doi:10.1016/j.visres.2012.09.012. Accessed March 9, 2019.
315. Byrne LC, Dalkara D, Luna G, et al. Viral-mediated RdCVF and RdCVFL expression protects cone and rod photoreceptors in retinal degeneration. *The Journal Of Clinical Investigation*. 2015;125(1):105-116. doi:10.1172/JCI65654. Accessed March 10, 2019.
316. Yang Y, Mohand-Said S, Danan A, et al. Functional cone rescue by RdCVF protein in a dominant model of retinitis pigmentosa. *Molecular Therapy: The Journal Of The American Society Of Gene Therapy*. 2009;17(5):787-795. doi:10.1038/mt.2009.28. Accessed March 10, 2019.
317. Elachouri G, Lee-Rivera I, Clérin E, et al. Thioredoxin rod-derived cone viability factor protects against photooxidative retinal damage. *Free Radical Biology & Medicine*. 2015;81:22-29. doi:10.1016/j.freeradbiomed.2015.01.003. Accessed March 10, 2019.

318. Ait-Ali N, Fridlich R, Millet-Puel G, et al. Rod-derived cone viability factor promotes cone survival by stimulating aerobic glycolysis. *Cell*. 2015;161(4):817-832. doi:10.1016/j.cell.2015.03.023. Accessed March 10, 2019.
319. Yu DY, Cringle SJ, Su EN, Yu PK. Intraretinal oxygen levels before and after photoreceptor loss in the RCS rat. *Investigative Ophthalmology & Visual Science*. 2000;41(12):3999-4006. <http://pointloma.idm.oclc.org/login?url=http://search.ebscohost.com/login.aspx?direct=true&db=mnh&AN=11053305&site=ehost-live>. Accessed March 10, 2019.
320. Usui S, Oveson BC, Iwase T, et al. Overexpression of SOD in retina: need for increase in H₂O₂-detoxifying enzyme in same cellular compartment. *Free Radical Biology & Medicine*. 2011;51(7):1347-1354. doi:10.1016/j.freeradbiomed.2011.06.010.
321. Natoli R, Valter K, Chrysostomou V, Stone J, Provis J. Morphological, functional and gene expression analysis of the hyperoxic mouse retina. *Experimental Eye Research*. 2011;92(4):306-314. doi:10.1016/j.exer.2010.12.013. Accessed March 10, 2019.
322. Igarashi N, Matsuura M, Hashimoto Y, et al. Assessing Visual Fields in Patients with Retinitis Pigmentosa Using a Novel Microperimeter with Eye Tracking: The MP-3. *PLoS ONE*. 2016;11(11):1-10. doi:10.1371/journal.pone.0166666. Accessed March 10, 2019.
323. Campochiaro PA, Mir TA. The mechanism of cone cell death in Retinitis Pigmentosa. *Progress in Retinal & Eye Research*. 2018;62:24-37. doi:10.1016/j.preteyeres.2017.08.004. Accessed March 9, 2019.
324. Pruett RC. Retinitis pigmentosa: clinical observations and correlations. *Transactions Of The American Ophthalmological Society*. 1983;81:693-735. <https://www.ncbi.nlm.nih.gov/pmc/articles/PMC1312466/> Accessed March 10, 2019.
325. Gränse L, Ponjavic V, Andréasson S. Full-field ERG, multifocal ERG and multifocal VEP in patients with retinitis pigmentosa and residual central visual fields. *Acta Ophthalmologica Scandinavica*. 2004;82(6):701-706. doi:10.1111/j.1600-0420.2004.00362.x. Accessed March 10, 2019.
326. Sandberg MA, Weigel-DiFranco C, Rosner B, Berson EL. The relationship between visual field size and electroretinogram amplitude in retinitis pigmentosa. *Investigative Ophthalmology & Visual Science*. 1996;37(8):1693-1698. <https://iovs.arvojournals.org/article.aspx?articleid=2161792>. Accessed March 10, 2019.
327. Hood DC, Holopigian K, Greenstein V, Seiple W, Li J, Sutter EE, Carr RE. Assessment of local retinal function in patients with retinitis pigmentosa using the multi-focal ERG technique. *Vision Res*. 1998;38(1):163. [https://doi.org/10.1016/S0042-6989\(97\)00143-0](https://doi.org/10.1016/S0042-6989(97)00143-0). Accessed March 10, 2019.
328. Koyanagi Y, Murakami Y, Funatsu J, et al. Optical coherence tomography angiography of the macular microvasculature changes in retinitis pigmentosa. *Acta Ophthalmologica*. 2018;96(1):e59-e67. doi:10.1111/aos.13475. Accessed March 10, 2019.
329. Koustenis A, Harris A, Gross J, Januleviciene I, Shah A, Siesky B. Optical coherence tomography angiography: an overview of the technology and an assessment of applications for clinical research. *The British Journal Of Ophthalmology*. 2017;101(1):16-20. doi:10.1136/bjophthalmol-2016-309389. Accessed March 10, 2019.
330. Hamel C. Fundus of patient with retinitis pigmentosa, end stage (Pigment deposits are present all over the retina. Retinal vessels are very thin and optic disc is pale.) *Hamel Orphanet Journal of Rare Diseases*.; 2006 1:40 doi:10.1186/1750-1172-1-40. Accessed March 18, 2018.

- 331.Sahni JN, Angi M, Irigoyen C, Semeraro F, Romano MR, Parmeggiani F. Therapeutic challenges to retinitis pigmentosa: from neuroprotection to gene therapy. *Current Genomics*. 2011;12(4):276-284. doi:10.2174/138920211795860062. Accessed March 10, 2019.
- 332.Berson EL, Weigel-DiFranco C, Rosner B, Gaudio AR, Sanderber MA. Association of vitamin A supplementation with disease course in children with retinitis pigmentosa. *JAMA Ophthalmol*. 2018 May 1;136(5):490-495. doi:10.1001/jamaophthalmol.2018.0590. Accessed March 10, 2019.
- 333.Rayapudi S. Vitamin A and fish oils for retinitis pigmentosa. Schwartz SG, Wang X, Chavis P, eds. *Cochrane Database of Systematic Reviews*. 2013;(12). doi:10.1002/14651858.CD008428.pub2. Accessed March 10, 2019.
- 334.Bittner AK, Gould JM, Rosenfarb A, Rozanski C, Dagnelie G. A pilot study of an acupuncture protocol to improve visual function in retinitis pigmentosa patients. *Clinical & Experimental Optometry*. 2014;97(3):240-247. doi:10.1111/cxo.12117. Accessed March 10, 2019.
- 335.Bainbridge JWB, Mehat MS, Sundaram V, et al. Long-term effect of gene therapy on Leber's congenital amaurosis. *New England Journal of Medicine*. 2015;372(20):1887-1897. doi:10.1056/NEJMoA1414221. Accessed March 10, 2019.
- 336.Chader GJ1, Weiland J, Humayun MS. Artificial vision: needs, functioning, and testing of a retinal electronic prosthesis. *Prog Brain Res*. 2009;175:317-32. doi:10.1016/S0079-6123(09)17522-2. Accessed March 10, 2019.
- 337.Liu Y, Chen SJ, Li SY, et al. Long-term safety of human retinal progenitor cell transplantation in retinitis pigmentosa patients. *Stem Cell Research & Therapy*. 2017;8(1):209. doi:10.1186/s13287-017-0661-8. Accessed March 10, 2019.
- 338.Feltgen N, Walter P. Rhegmatogenous retinal detachment—an ophthalmologic emergency. *Dtsch Arztebl Int*. 2014; 111(1-2):12-22. doi:10.3238/arztebl.2014.0012. Accessed March 25, 2019.
- 339.Chandra A, Banerjee P, Davis D, Charteris D. Ethnic variation in rhegmatogenous retinal detachments. *Eye*. 2015;29(6):803-807. doi:10.1038/eye.2015.43. Accessed March 29, 2019.
- 340.Hikichi T, Yoshida A. Time course of development of posterior vitreous detachment in the fellow eye after development in the first eye. *Ophthalmology*. 2004 Sep;111(9):1705-7. Accessed March 26, 2019.
- 341.Hikichi T1, Hirokawa H, Kado M, Akiba J, Kakehashi A, Yoshida A, Trempe CL. Comparison of the prevalence of posterior vitreous detachment in whites and Japanese. *Ophthalmic Surg*. 1995 Jan-Feb;26(1):39-43. <https://www.ncbi.nlm.nih.gov/pubmed/7746623>. Accessed March 28, 2019.
- 342.Foster PJ, Jiang Y. Epidemiology of myopia. *Eye (London, England)*. 2014;28(2):202-208. doi:10.1038/eye.2013.280. Accessed March 25, 2019.
- 343.Go SL, Hoyng CB, Klaver CC. Genetic risk of rhegmatogenous retinal detachment: a familial aggregation study. *Arch Ophthalmol*. 2005;123(9):1237. doi:10.1001/archophth.123.9.1237. Accessed March 26, 2019.
- 344.Oh J-H, Oh J, Roh HC. Vitreous Hyper-Reflective Dots in Optical Coherence Tomography and Retinal Tear in Patients with Acute Posterior Vitreous Detachment. *Current Eye Research*. 2017;42(8):1179-1184. doi:10.1080/02713683.2017.1289226. Accessed March 27, 2019.

345. Wilkinson CP. Interventions for asymptomatic retinal breaks and lattice degeneration for preventing retinal detachment. *Cochrane Database of Systematic Reviews*. 2014;(9). 10.1002/14651858.CD003170.pub4. Accessed April 3, 2019.
346. Mattioli S, Curti S, De Fazio R, et al. Occupational lifting tasks and retinal detachment in non-myopics and myopics: extended analysis of a case-control study. *Safety And Health At Work*. 2012;3(1):52-57. doi:10.5491/SHAW.2012.3.1.52. Accessed March 27, 2019.
347. Nakazawa T, Kayama M, Ryu M, et al. Tumor necrosis factor-alpha mediates photoreceptor death in a rodent model of retinal detachment. *Investigative Ophthalmology & Visual Science*. 2011;52(3):1384-1391. doi:10.1167/iovs.10-6509. Accessed April 5, 2019.
348. Stewart MW, Browning DJ, Landers MB. Current management of diabetic tractional retinal detachments. *Indian Journal Of Ophthalmology*. 2018;66(12):1751-1762. doi:10.4103/ijo.IJO_1217_18. Accessed April 7, 2019.
349. Gishti O, van den Nieuwenhof R, Verhoekx J, van Overdam K. Symptoms related to posterior vitreous detachment and the risk of developing retinal tears: a systematic review. *Acta Ophthalmologica*. 2019. doi:10.1111/aos.14012. Accessed March 27, 2019.
350. Baker N, Amini R, Situ-LaCasse EH, et al. Can emergency physicians accurately distinguish retinal detachment from posterior vitreous detachment with point-of-care ocular ultrasound? *American Journal of Emergency Medicine*. 2018;36(5):774-776. doi:10.1016/j.ajem.2017.10.010. Accessed April 5, 2019.
351. Gorovoy IR, Porco TC, Bhisitkul RB, de Juan E Jr, Schwartz DM, Stewart JM. Same-Day Versus Next-Day Repair of Fovea-Threatening Primary Rhegmatogenous Retinal Detachments. *Seminars In Ophthalmology*. 2016;31(3):219-225. doi:10.3109/08820538.2014.936619. Accessed March 27, 2019.
352. Delaney YM, Oyinloye A, Benjamin L. Nd:YAG vitreolysis and pars plana vitrectomy: surgical treatment for vitreous floaters. *Eye (London, England)*. 2002;16(1):21-26. <http://search.ebscohost.com.pointloma.idm.oclc.org/login.aspx?direct=true&db=mnh&AN=11913884&site=ehost-live>. Accessed April 8, 2019.
353. Shah R, Byanju R, Pradhan S, Ranabhat S. Factors Affecting the Outcome of Scleral Buckling Surgery for Primary Rhegmatogenous Retinal Detachment. *Journal of Ophthalmology*. November 2018:1-4. doi:10.1155/2018/9016302.
354. Cohen E, Rosenblatt A, Bornstein S, Loewenstein A, Barak A, Schwartz S. Wide-angled endoillumination vs traditional scleral buckling surgery for retinal detachment – a comparative study. *Clinical Ophthalmology*. 2019;13:287-293. doi:10.2147/OPTH.S182751. Accessed April 5, 2019.